HISTOLOGICAL AND HISTOPATHOLOGICAL STUDIES IN HETEROPNEUSTES FOSSILIS (BLOCH) LIVER

BHARTI D. SHRINIWAS

PGT DEPARTMENT OF ZOOLOGY,
RTM NAGPUR UNIVERSITY, NAGPUR-440033. MAHARASHTRA, INDIA
dr.bhartishriniwas@gmail.com

ABSTRACT: Fishes play a vital role in food and nutrition all over the world. Diseases in fishes occur due to interaction of pathogens and stressful environment. Histology and histopathological studies in *Heteropneustes fosilis* (Bloch) liver reflect the overall health of entire population in ecosystem. Histopathological biomarker in *Heteropneustes fosilis* liver is based on experimental data to support the bacterial and fungal infection induced changes in liver tissue. This research aims to observe the effect of infection on liver. Liver is a major site of many biotransformation reactions, it play major role in digestion of food, energy metabolism, storage and synthesis of proteins. It can therefore concluded that infections resulted in following histological alterations: liver necrosis, cellular infiltration, vacuolar degeneration, cytoplasmic vacuolation in present study are indicators of poor fish health deteriorating the metabolic activity there by affecting protein and amino acids content.

KEYWORDS: Histology, Histopathology, Liver, *Heteropneustes fosilis*

INTRODUCTION

Various reports of fish mortality from the different regions of the country occurring in water bodies causing economic losses due to diseases. (Mohan and Bhatta, 2002) However, inadequate reporting and monitoring of such information about fish diseases has yet to find a place in the framework of fisheries management practices prevailing in the country (Das,2002).Liver is one of the most intensively investigated organs among vertebrates. *Pseudomonas aeruginosa* and *Staphylococcus epidermitis* in the surface lesions as well as in the liver of sick fishes reported by Kar et.al.,(2000).The study conducted to investigate the histological structures of liver in *Tilapia zilli* and *Solea vulgaris* obtain from Lake Quran , Egypt by Mohamed (2009) showed vacuolar degeneration in the hepatocytes, focal areas of necrosis and fibrosis, aggregations of inflammatory cells between the hepatocytes, dilation and congestion in blood sinusoids and thrombosis formation in central veins.

Histology deals with the microscopic study of biological tissue in normal healthy fish. On the other hand histopathology deals with the study of pathological changes induced in microscopic structure of body tissue. Any peculiar type of alteration in tissue (liver) may indicate the effect of disease. Therefore study of liver histopathology is of utmost importance in the diagnosis of infectious diseases. In *H. fosilis*, it is observed that the discoloration of liver, whirling movement, skin ulceration white and black patches over body. Histopathological study thus gives us useful data regarding significant damage to the internal organs prior to external manifestation.

MATERIAL AND METHODS

Heteropneustes fosilis popularly known as singhi reported to be highly nutritive, recuperative and esteemed for its invigorating qualities. Singhi is popular because it can be cultivated in swampy areas and derelicts water bodies without involving costly reclaimation. It can be easily stored and transported live to consumers.

SCREENING OF FISHES

Screening of normal and infected fishes was done on the basis of following observation. Normal fishes show good color, gills reddish in color and fish body is without any gross lesions.

GROSS PATHOLOGICAL OBSERVATIONS

Heteropneustes fosilis collected on every visit were carefully observed for external gross lesions and specific signs of disease by external and internal examination. The infected fishes were found to be weak and showed whirling movements, coming to surface, dull skin, gills pale, slimy with small haemorrhages on body.

SAMPLE COLLECTION

The normal and moribound fishes (Fig 1&2) with typical sign and symptoms of infections were biopsied and sampled for histological as well as histopathological evaluation.The samples of liver of about 1cm^3 were excised and fixed in aqueous Bouins fixative (18-24 hours).The fixed tissue was dehydrated in ascending grades of alcohol, cleared in xylene, embedded in paraffin wax, sectioned at 4-5 µm thickness, mounted on albuminized slide, stained with Haematoxylene Eosin and mount in DPX. Stained slide were then examined under microscope and photographed.

OBSERVATIONS

Clinical Signs and Symptoms

The moribound fishes kept in aquarium shows following signs and symptoms: Dullness of skin, (Fig.3) skin ulceration on body (Fig 4a& b), ulcer in anal and caudal region, tail and fin rot, black patches over body, liver showing pale color with swollen round edges (Fig 6). The distribution of lesions is variable and includes mouth, back trunk and caudal peduncle.

fig1. *H.fossilis* showing dark brown color.
fig 2.Infected *H.fossilis.*
fig 3.Dullness of skin in infected *H.fossilis.*
fig 4a& b. Infected *H.fossilis* showing skin ulceration over body.

Liver Histology (Normal)

Liver is a bilobed structure occupying one fourth of abdominal cavity as orange red (Fig 5) mass. Histologically, liver is made up of large no. of polyhedral hepatic cells, clear cellular border lines, homogenous cytoplasm, prominent nucleus and nucleolus. They appear in rows like column called hepatic cords. In between hepatic cells, branches of hepatic veins and hepatic ducts were observed (Fig 7).

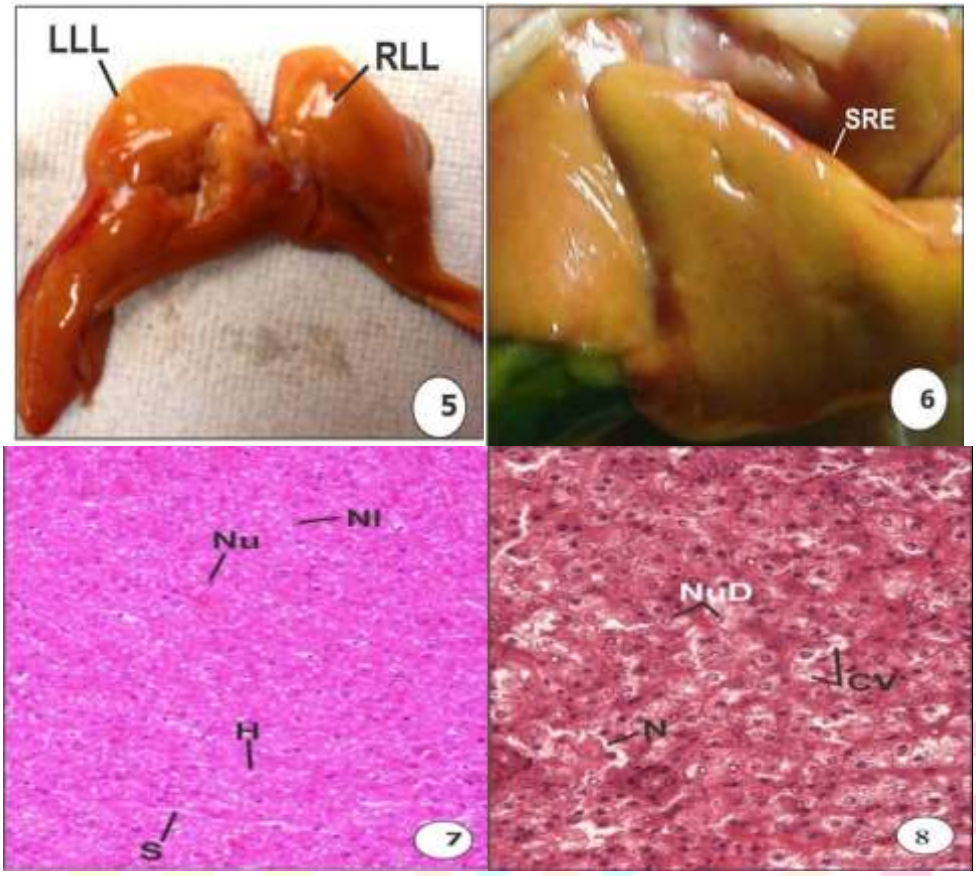

fig 5.Liver showing orange red color of normal *H. fossilis.*
fig 6. Liver showing pale yellow color of infected *H. fossilis with* swollen round edges (SRE)
fig 7.T.S. liver of normal *H.fossilis* (H.EX200).
fig 8. T.S. liver showing necrosis (N) {*H.fossilis* (H.EX400)}.

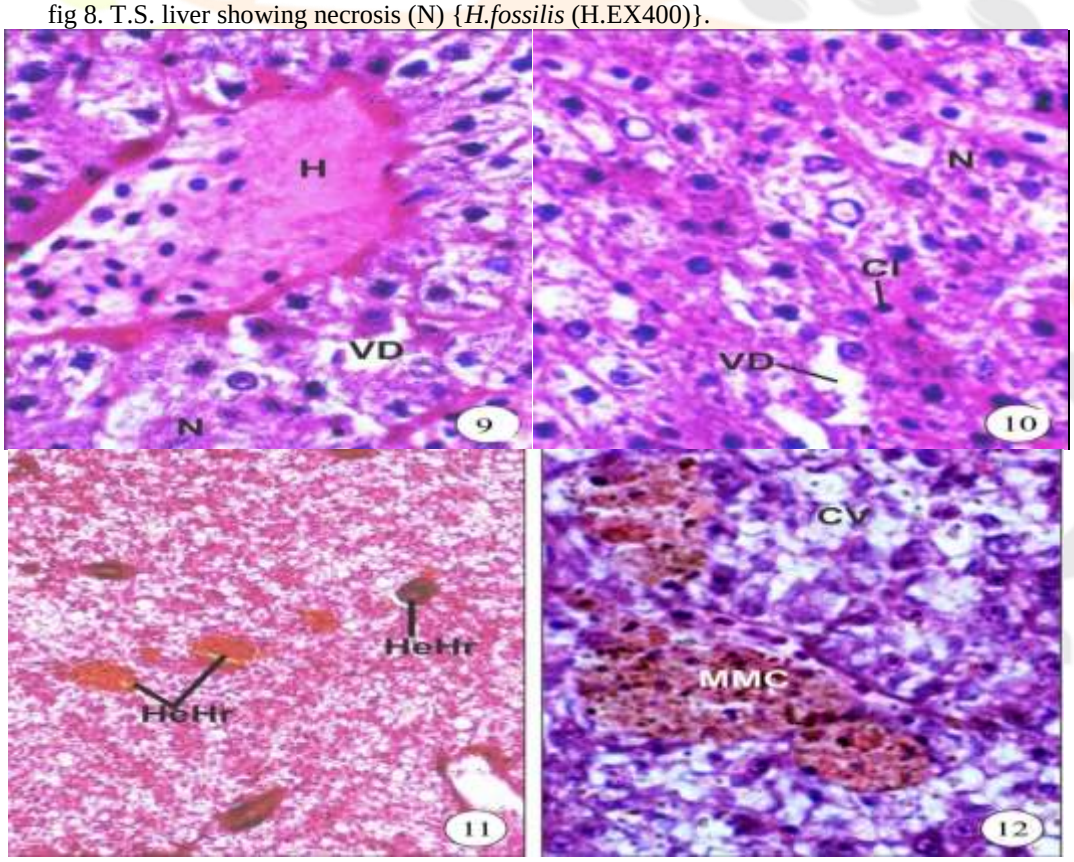

fig 9. T.S. liver showing vacuolar degeneration (VD) and necrosis (N) {*H.fossilis* (H.EX1000)}.
fig 10. T.S. liver showing cellular infiltration (CI) necrosis (N) {*H.fossilis* (H.EX1000)}.
fig 11. T.S. of *H.fossilis* liver showing hepatocellular haemosiderosis (HeHr) (H.EX400).
fig 12. T.S. of *H.fossilis* liver showing melanomacrophage centers (MMC) (H.EX1000).

Liver Histopathology

The histopathological response was represented by necrosis in hepatic cells (fig.8) vacuolar degeneration (fig.9), cellular infiltration, cytoplasmic vacuolation (fig.10).The major histopathological difference between normal and infected liver was hepatocellular haemosiderosis (fig.11) melanomacrophage centers (fig.12).

CONCLUSION

Metabolism of food items and their storage is important functions of the liver. Hence liver is susceptible to infections which cause metabolic disturbances. The liver of normal fish showed regularly arranged hepatocytes with hepatic veins and hepatic ducts around the vascular system (sinusoids).

A variety of histopathological changes in liver are necrosis in hepatic cells, vacuolar degeneration, cellular infiltration and cytoplasmic vacuolation and presence of haemosiderosis in hepatocytes. Also, the results showed the presence of melanomacrophage centers in hepatic parenchyma of all studies fishes. Melanomacrophage centers were big and contained large amount of cytoplasm along with nucleus. Based on the result of this research it is concluded that infection damages fish liver.

DISCUSSION

Diseases, in fishes develop as the result of exposing a host to an infectious agent (Snieszko, 1973) but in most of the instances diseases occur as a result of complex interaction between pathogen, fish and environmental stress which affect the susceptibility of host to diseases. In the present study fishes shows external signs of infection like excess mucus, dullness of skin, skin ulceration on body, ulcer in anal and caudal region, tail and fin rot, black patches over body. Udomkusonsri, (2003) reported similar external signs of bacterial and fungal infections on the body of the channel catfish, rainbow trout, striped bass, gold fish, salmon and American eel.

In *H. fossilis* liver shows pale color with swollen round edges revealed vacuolar degeneration. Roy et.al, (2006) and Kar et. al., (2000) also reported vacuolar degeneration of hepatocytes in sick fish infected with *E.coli* and *P. aeruginosa*.Necrosis in hepatic cells can be caused by several factors such as infectious agents (fungi, bacteria, and parasites) and affect the blood supply to particular tissue. All these disturbances can trigger specific damage to the cell (Kotob et. al.2016).The presence of cellular infiltration and necrosis can be utilized as biomarkers as pointed out by Paolini et. al., (2005) in chubs (*Leuciscus cephalus*) and brown trout (*Salmo trutta*) and Yuksel et. al., (2006) in carp.

The presence of pigment haemosiderin was observed in hepatocytes in *H. fossilis.* Haemosiderin in the liver represent as product of haemoglobin degradation that has been filtered out by the lymphoid macrophage system (Khan et al., 1994).Pigment cells formation is chronic inflammatory reaction reported by Matushima et al., (2006).

During the present study, MMC's were one of features in fish liver. Vethaak et al., (1995) observed an association between hepatic MMC's and infection. MMC's also known as macrophage aggregates, MMC's increase in size or frequency during environmental stress and considered as reliable biomarkers for water quality in terms of both deoxygenation and infections (Agius and Roberts, 2003). Fayed,(2004) explained MMC's as a type of intercytoplasmic storage disorder in which breakdown of haemoglobin leads to accumulation of pigment as brown deposits within hepatic tissues occur and are called hepatocellular haemosiderosis (Brand, 2000).

ACKNOWLEDGEMENT: Author was grateful to RTM Nagpur University Nagpur for providing lab facility to carry out her research work.

REFERENCES

1. Agius C. and Roberts R.J. (2003) Melano macrophage centers and their role in fish pathology. *J.Fish Dis*.26 (9):499-509.

2. Brand D., Eickhoff C., Cretney W., Law F. and Reid R. (2000) Liver histopathology and pah bile metabolites found in English sole (*Pleuronectes vetulus*).*Sym.Proc.Fish Toxicol*.43-53.

3. Das M.K. (2002) Social and economic impacts of disease in inland open-water and culture –based fisheries in India. In: Arthur J.R., Phillips M.J., Subasinghe R.P., Reantaso M.B. and Macrae I.H. (eds.)Primary aquatic animal health care in rural, small scale, aquaculture development. *FAO Fish.Tech.Pap.No*.406:333-344.

4. Fayed D.B.M. (2004) Aspects of Manzalah lake pollution on Mugil species. *M.Sc. Thesis*, Ain Shams Univ., Egypt.

5. Kar D., Dey S.C., Roy A. and Mandal M. (2000) Epizootic ulcerative syndrome in fish at Barak valley, Assam, India.

6. Khan R.A., Barker D.E., Hooper R., Lee E.M., Ryan K. and Nag K. (1994) Histopathology in Winter flounder (*Pleuronectes americanus*) living adjacent to a pulp and paper mill. *Arch.Environ.Contam.Toxicol*.26:95-102.

7.Kotob M.H., Menanteau- Ledouble S., Kumar g., Abdelzaher A., Elmatbouli M. (2016) The impact of co-infection on fish: A review.*Vet.Res*.47:98.

8. Matushima E.R., Longatto A., Kanamura C.T. and Sinhorini I.L. (2006) Experimental chronic granulomatous inflammatory process in fish: A morphological, ultrastructural and immunocytochemical study. *Brazillian J.Vet.Res.Anim.Sci*.33 (1):5-10.

9. Mohan C.V. and Bhatta R. (2002) Social and economic impacts of aquatic animal health problems on aquaculture in India. In: Arthur J.R., Phillips M.J., Subasinghe R.P., Reantaso M.B. and Macrae I.H. (eds.) Primary aquatic animal health care in rural, small scale, aquaculture development.*FAO Fish.Tech.Pap.No*.406:63-75.

10. Mohamed fatma A.S. (2009) Histopathological studies on *Tilapia zilli* and *Solea vulgaris* from Lake Qarun, Egypt. *World J.Fish Marine Sci*.1 (1):29-39.

11.Paolini A., Berti M., D'Angelo A. and Giansante C. (2005) Use of histopathological indicators on chubs (*Leuciscus cephalus*) and brown trout (*Salmo trutta fario*) in evaluating river environments. *Veterinaria Italians*.41 (3):189-198.

12.Roy P., Edwin P.G., Purushothaman V., Murlimanohar B. and Chandramohan A.(2006) *Aeromonas hydrophilla* infection in Koi carp and Gold fish. *Indian J. Animal Sci.*76 (7):566-568.

13. Snieszko S.F. (1973) Recent advances of scientific knowledge and developments pertaining to diseases of fishes. *Adv.Vet.Sci.Comp.Med.*17:291-314.

14. Udomkusonsri P. (2003) Pathogens of acute ulceration response (AUR) in fish. *PhD Thesis, Comparative Biomed. Sci.* North Carolina State University, Raleigh, USA.

15. Vethaak AD. And Rheinallt T. (1995) Fish disease as monitor for marine pollution: The case of North Sea. *J. Rev. Fish Biol*. 2(1):1-32.

16.Yuksel H.L., Ural M., Dorucu M. and Karadas E. (2006) Pathological changes in the carp exposed to iron sulphate. *Indian Vet.J.*83:150-152.