IJNRD.ORG ISSN : 2456-4184
INTERNATIONAL JOURNAL OF NOVEL RESEARCH AND DEVELOPMENT (IJNRD) | IJNRD.ORG
An International Open Access, Peer-reviewed, Refereed Journal

Ultrasound and Appendicitis: evaluation of correlation between USG diagnosis and pathological diagnosis

Dr Pratik Gond, Dr Kishor Gadhave, Dr Manideep T, Dr Pranjal Tanter, Dr Shreya Pakkal..

ABSTRACT

Aim : To evaluate the correlation between appendi-ceal size measured by USG of theabdomen and pelvis and the size of surgically removedappendixes on gross pathological examination.

Materials and methods: In this prospective study, an initial database of 116 patients was collected from 1 January 2021 to 31 august 2022, Diagnostic criteria for inclusion in the study were an evaluation for abdominal pain by USG and had met size criteria for a radiological diagnosis of acute appendicitis (including, but not limited to, >6 mm), a subsequent surgical appendectomy performed by a surgeon, followed by measurement of the gross appendiceal specimen by VERNIERS CALIPER, all at a single institution.

Results: The mean size of appendixes meeting the USG size criteria of appendicitis was 8.89cm and that of the surgical pathology specimens was 12.84cm. The pathological diagnosis of acute appendicitis was confirmed in majority cases The mean absolute difference in USG size versus pathological size was 3.94 mm.

Conclusion: The data reveal a strong positive correlation in ability of USG to predict the presence of acute appendicitis, with correlation in the size estimate of acutely inflamed appendixes, as imaged on USG, and the pathological specimen status after appendectomy.

INTRODUCTION

In the medical community, accurate diagnosis of acute appendicitis has received considerable attention. Some writers claim that the most typical cause of severe abdominal pain requiring surgical intervention in the Western World is acute appendicitis. 1 The use of particular diagnostic criteria in the work-up and evaluation of suspected acute appendicitis has been recommended in several articles that have looked at potential best practises for detecting this ailment. These have included anything from physical examination and palpation to confirming laboratory values like the white blood cell count and C-reactive protein concentration. They have also included the use of radiographic evaluation, including but not limited to the use of ultrasound and CT. Still, several large prospective studies reveal that up to 30% of appendices removed are benign, and up to 50% of individuals hospitalised for probable acute appendicitis are later discovered to have been misdiagnosed2. 3USG has been shown to have high diagnostic accuracy in patients suspected of having acute appendicitis.[4] Reported USG signs of appendicitis include direct visualisation of an abnormal appendix, periappendiceal inflammatory changes,[5] adjacent phlegmon and/or abscess, intraperitoneal free air and/or appendicolith, appendiceal wall enhancement or wall defect, and lack of contrast or air in the appendix.[6] However, the dilated tubular appendix is not always directly visualised, because of technical factors, perforation or abscess formation. Furthermore, there is much variability between the USG appearance of the acutely inflamed appendix and that of the normal appendix. It has been reported that the diameter of a normal appendix can range from 3.0 to 18.0 mm, with as many as 42% being .6.0 mm.[7] This is in contradiction to the reported observation that an outer appendiceal diameter of >6 mm is a sign of acute appendicitis, providing a high sensitivity of 100%, but limited specificity of 68% on ultrasound imaging.[8] Nonetheless, the cut-off point most commonly used for both ultrasound and USG imaging in the diagnosis of acute appendicitis is 6 mm, regardless of patient age,[9] with the caveat that this diagnostic criterion is more useful in excluding acute appendicitis, than in confirming it.[8]

It should be noted that a recent meta-analysis performed by Doria et al[9] found no statistically significant difference in the ability of USG or CT to predictacute appendicitis, regardless of patient age, using a cut-off value of 6 mm for the diagnosis. In addition, Simonovsky[10] showed that, although there was a minimally significant difference (p=0.042) in maximal mural thickness of the normal appendix in children up to 6 years of age relative to those of adolescents and adults (ages 16–82), evaluating such differences would necessitate measurement precision ,0.5 mm, thought to be relatively unlikely to be achieved in daily practice, and concluded that the upper value of the normal appendiceal mural thickness is 3 mm, regardless of age.As great emphasis is placed on the size of the appendix in the evaluation of acute appendicitis, a study assessing the ability of USG to predict the true diameter of the pathological specimen would be helpful in confirming the capacity of USG to predict a pathological state.

Thus, we sought to retrospectively evaluate the appendiceal size measured by USG, meeting diagnostic size criteria for acute appendicitis, against that of the surgically removed gross pathological specimen in a tertiary care medical centre. Although many previous investigations have assessed the ability of USG to accurately diagnose acute appendicitis, as far as we know, none has specifically looked at the correlation between appendiceal size measured by USG and that of the pathological specimen.

MATERIALS AND METHODS

In this prospective study, an initial database of 116 patients was collected from 1 January 2021 to 31 august 2022, Diagnostic criteria for inclusion in the study were an evaluation for abdominal pain by USG and had met size criteria for a radiological diagnosis of acute appendicitis (including, but not limited to, >6 mm), a subsequent surgical appendectomy performed by a surgeon, followed by measurement of the gross appendiceal specimen by VERNIERS CALIPER, all at a single institution.

Radiological criteria for the diagnosis of acute appendicitis were appendix size (>6 mm, except in the case of suspected perforation), periappendiceal fat-stranding and/or inflammatory changes, lack of intraluminal air in the appendix, appendiceal wall thickening and/or enlargement, presence of an appendicolith, and presence of surrounding or adjacent intraperitoneal free gas collections.

RESULTS

Pathologically proven acute appendicitis was confirmed in 111 of the 116 patients, yielding a positive predictive value of 95.68 % at our institution over this 2-year period. Table 1 lists the ranges, mean values and standard deviations of all 116 cases. The confirmed cases of acute appendicitis consisted of 56 female and 60 male patients whose Mean age was 34.64 years. The mean size of appendixes meeting the USG size criteria of acute appendicitis was 10.3 mm (range 6.0–24.0; 95% CI for mean 9.342 to 11.17; SD 2.24). The mean size of the surgical pathology specimens was 12.84 mm (range 4.0–22.0; 95% CI for mean 9.441 to 11.38; SD 2.58).

The Pearson product–moment correlation coefficient (r) for the comparison of CT-measured appendiceal size with that of the gross pathological specimens was calculated to be 0.909, which corresponds to a coefficient of determination value (r^2) of 0.893 (p,0.001 for one-tailed Student t test). The slope of the linear correlation was 0.5788. The mean absolute difference in USG size versus pathological size was 3.984 mm (range =0.0–10.0; 95% CI for mean 1.589 to 2.847; SD 2.35). Figure 1 is a graphical representation of USG size versus pathological correlation. The appendixes of all subjects had diameters of >6 mm, as measured by USG (as defined by the inclusion criteria). Of the 116 pathologically proven cases of acute appendicitis, none of the corresponding specimens were found to measure less than 6.0 mm. Of the 116 cases, only five were found to be non-pathological on gross and microscopic inspection, and these had the diameter less than 6.0 mm on measuring with verniers calliper.

Table 1 Correlation of USG -measured appendiceal size with pathological value in 116 subjects

	Range (mm)	Mean (mm)	Variance (mm)	SD
USG value	5.0–17.0	8.896	5.03	2.24
Pathology value	9.0–21.0	12.84	6.66	2.58

DISCUSSION

Evaluation of the data reveals a strong correlation in the ability of USG to predict the presence of acute appendicitis in our sample (positive predictive value 95.68%). Of the 116 pathologically proven cases of acute appendicitis in one was the gross specimen diameter 6.0 mm; a diagnosis of perforated acute appendicitis was made. In addition to the generally accepted size criterion used to diagnose acute appendicitis, additional signs include direct visualisation of an abnormal appendix, periappendiceal inflammatory changes,[5] adjacent phlegmon and/or abscess, intraperitoneal free air and/or appendicolith, appendiceal wall enlargement or wall defect or air in the appendix.[6] Yet, neither of the Four cases for which a USG diagnosis of acute appendicitis was made (outer diameter >6 mm) but later found to be non-pathological was reported to have additional specific usg diagnostic signs of acute appendicitis The normal diameter of the appendix can be as high as 12.8 mm. 91.0% of normal appendices are larger than 6 mm in the study by by Willekens et al [11] . The normal wall thickness is larger than 3 mm in 8% of normal appendixes. Hence, relying on appendix size alone may lead to misdiagnosis and mismanagement as state by Willekens et al [11] Sonography is relatively inexpensive, rapid, is noninvasive, and requires no patient preparation or contrast material administration. With regard to the accuracy of sonography compared with CT in the diagnosis of acute appendicitis, our sonography results are similar to those of other reports [14-20] . In our study, 5 (4.8%) of the 112 patients were found to have a normal appendix at
surgery, but the USG findings were positive for appendicitis

The source of discrepancy lies in the slight lack of inter-rater reliability, as alluded to above in the blinded re-evaluation of some of the studies. This is further compounded by the subjective interpretation of findings related to the elusive appendix. In addition, there probably exists a small, but significant, range of potential measurements for the appendix, given the specific cross-section that is measured, as well as the extent to which the image is enlarged before measurement.

A limitation of this study may be that the radiologists were forced to state whether appendicitis was acute. There was no room for indeterminate answers. We also disregarded the impact of the different degrees of experience among the radiologists in analyzing sonography for acute appendicitis. Disregarded also was the body habitus; in obese patients, sonography may be more difficult.

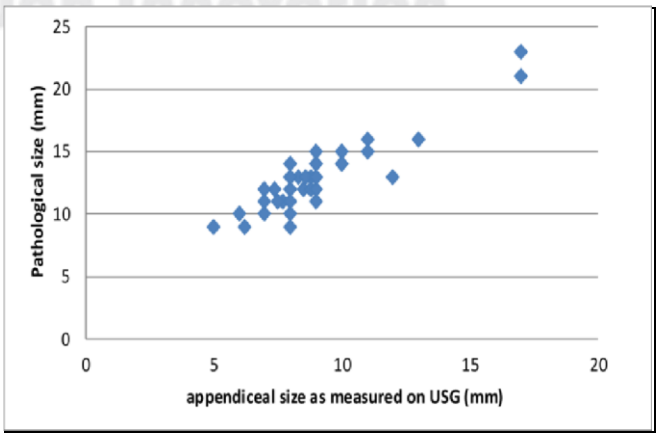

FIGURE 1 Correlation of appendiceal size measured by USG with that of gross specimen pathology in 116 subjects. The slope of the linear correlation was calculated to be 0.5788, with a Y-intercept of 4.4759 (not shown).

FIGURE 2

Pathological image of appendix showing diameter being measured
with verniers calliper

FIGURE 3

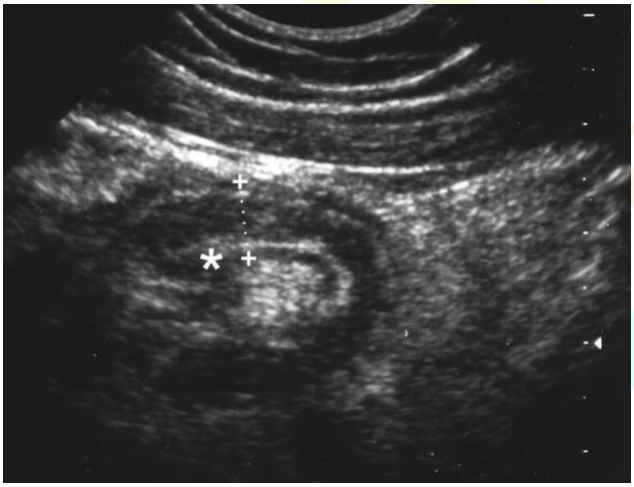

Sonogram of 29-year-old man shows acute appendicitis with incompressible 9-mm appendix (asterisk) and echogenic incompressible periappendicular inflamed fat. Dotted line shows enlarged appendices

In conclusion, many significant contributions have been made in the radiological diagnosis and characterization of acute appendicitis. Our data reveal a strong correlation in the ability of USG to predict the presence of acute appendicitis in our sample, consistent with previously reported data. Our data also suggest a strong positive correlation in the size estimate of acutely inflamed appendixes, as imaged on USG, with the pathological specimen status after appendectomy (r = 0.909). Given the presence of multiple confounding variables in our study and limitations it is our belief that this strong positive correlation is an underestimate of the true ability of between USG-measured appendiceal size and that of the gross specimen will probably shed light on these initially promising data.

Finally, our data concur with previous reports that, when the appendix is identified on USG and measures 6 mm and above, confidence should be given to the prediction of a pathological diagnosis of acute appendicitis.

In our opinion, the introduction of sonography as a standard procedure in the workup of acute appendicitis can be worthwhile only if the surgeon can rely fully on sonography performed in the hospital. Concern still exists that the overuse or reliance of radiologic tests may distract from careful and timely clinical evaluation and not add significantly to establishing the diagnosis. How high should accuracy of sonography in acute appendicitis be to convince the surgeon not to operate? If a small risk of a perforated acute appendicitis is still present even when sonography show a normal appendix, most surgeons will neglect the benefits of these additional radiologic tools. Wilson et al.[11] were the first to design a prospective study to determine whether CT and sonography affect a surgeon's decision-making process in acute appendicitis. We believe that further prospective studies are needed to offer a diagnostic pathway in which sonography and observation can be valuable tools in managing acute appendicitis

REFERENCES

1. Graffeo CS, Counselman FL. Appendicitis. Emerg Med Clin North Am 1996;14:653–71.
2. Kessler N, Cyteval C, Gallix B, et al. Appendicitis: evaluation of sensitivity, specificity, and predictive values of US, Doppler US, and laboratory findings. Radiology 2004;230:472–8.
3. Deutsch A, Shani N, Reiss R. Are some appendectomies unnecessary: an analysis of 319 white appendices. J R Coll Surg Edinb 1983;28:35–40.
4. Balthazar EJ, Megibow AJ, Siegel SE, et al. Appendicitis: prospective evaluation with high-resolution CT. Radiology 1991;180:21–4.
5. Curtin KR, Fitzgerald SW, Nemcek AA Jr, et al. CT diagnosis of acute appendicitis:
imaging findings. AJR Am J Roentgenol 1995;164:905–9.
6. Balthazar EJ, Birnbaum BA, Yee J, et al. Acute appendicitis: CT and US correlation in 100 patients. Radiology 1994;190:31–5.
7. Tamburrini S, Brunetti A, Brown M, et al. CT appearance of the normal appendix in adults. Eur Radiol 2005;15:2096–103.
8. Rettenbacher T, Hollerweger A, Macheiner P, et al. Outer diameter of the vermiform appendix as a sign of acute appendicitis: evaluation at US. Radiology 2001;218:757–62.
9. Doria AS, Moineddin R, Kellenberger CJ, et al. US or CT for diagnosis of appendicitis in children and adults? A meta-analysis. Radiology 2006;241:83–94.
10. Simonovsky V. Normal appendix: is there any significant difference in the maximal mural thickness at US between pediatric and adult populations? Radiology 2002;224:333–7.
11. Balthazar E, Birnbaum B, Yee J, Megibow A, RoshkowJ, Gray C. Acute
12. appendicitis: CT and US correlationin 100 patients. Radiology 1994;190:31–35
13. Wilson EB, Cole JC, Nipper ML, Cooney DR, Smith RW. Computed tomography and ultrasonography in the diagnosis of appendicitis. Arch Surg 2001;136:
14. 670–675
15. Pickuth D, Heywang-Kobrunner H, Spielmann RP. Suspected acute appendicitis: is ultrasonography or computed tomography the preferred imaging technique? Eur J Surg 2000;166:315–319
16. Horton M, Counter SF, Florence MG, Hart MJ. A prospective trial of computed tomography and ultrasonography for diagnosing appendicitis in the atypical patient. Am J Surg 2000;179:379–381
17. Wise SW, Labuski MR, Kasales CJ, et al. Comparative assessment of CT
18. and sonographic techniques for appendiceal imaging. AJR 2001;176:933–941
19. Sivit CJ, Applegate KE, Stallion A, et al. Imaging evaluation of suspected appendicitis in a pediatric population: effectiveness of sonography versus CT.
20. AJR 2000;175:977–980
21. Kaiser S, Frenckner B, Jorulf HK. Suspected appendicitis in children: US and CT—a prospective randomizedstudy. Radiology 2002;223:633–638
22. Wilson EB, Cole JC, Nipper ML, Cooney DR, Smith RW.
23. tomography and ultrasonography in the diagnosis of appendicitis. Arch Surg 2001;136: 670–675
24. Willekens I, Peeters E, De Maeseneer M, de Mey J (2014) The Normal Appendix on CT: Does Size Matter? PLoS ONE 9(5): e96476. doi:10.1371/journal. pone.0096476.
25. Birnbaum B, Wilson S. Appendicitis at the millennium. Radiology 2000;215:337–348