IJNRD.ORG ISSN : 2456-4184
INTERNATIONAL JOURNAL OF NOVEL RESEARCH AND DEVELOPMENT (IJNRD) | IJNRD.ORG
An International Open Access, Peer-reviewed, Refereed Journal

A Case of Spontaneous Spinal Subdural Hematoma with Paraplegia: A Case Report.

[1]Dr Mukesh Kumar, [2]Dr Sushil Kumar, [3]Dr Rabindra Kumar

[1]Junior Resident, [2] Assistant Professor, [3]Senior Resident
[1]Department of Anesthesiology and Critical Care,
[1]Darbhanga Medical College and Hospital, Darbhanga, India

Abstract : **Background** : Spinal subdural hematoma is serious but rare complication . We report a patient of spinal subdural hematoma at site far from needle puncture site, following spinal anaesthesia for caesarean delivery**. Case presentation**: A 22year old parturient presented at emergency of OBG dept. Spinal anaesthesia was given at L3- L4 space which was atraumatic and given in a single successful attempt and caesarean delivery was uneventful. On the 4th post- operative day patient presented with sudden onset of severe upper back pain and weakness in both lower- limb leading to flaccid paralysis. MRI images showed spinal subdural hematoma at D3-D4 level producing cord compression. **Discussion**: Spinal subdural hematoma brings about devastating neurological dysfunction with significant morbidity and mortality. MRI is the standard modality in the evaluation of spinal cord injuries visualising not only the hematoma but also other is spinal cord pathologies. **Conclusion**: Spontaneous spinal subdural hematoma can occur without any known pathology or remarkable trauma. It can cause compression of the spinal cord and should be ruled out in any patient presenting with neurological dysfunction. It can be early diagnosed with the help of MRI and early initiation of conservative treatment improves the prognosis of patient**.**

INTRODUCTION

Spinal subdural hematoma is serious but rare complication. Spinal anesthesia is extensively used procedure for many surgeries.We report a patient of spinal subdural hematoma at site far from needle puncture site, following spinal anesthesia for caesarean delivery.

Case Presentation :

A 22year old parturient gravida 2, parity 1, presented at emergency of our hospital with 38 weeks 4 days of gestation. On examination she was afebrile with stable vital signs. Spinal anesthesia was given at L3-L4 space which was atraumatic and given in a single successful attempt for emergency caesarean delivery. Intraoperative period was uneventful. On the 4th post-operative day she complain of sudden onset of severe upper back pain and weakness in both lower limb leading to flaccid paralysis. No complain of upper limb weakness. Not associated with headache, vomiting, convulsion. Her neurologic examination was remarkable for lower extremity paraplegia with 0/5 motor strength, absent lower extremity reflexes, no proprioception, and complete sensory loss bilaterally uptoT4. No complaint of upper limb weakness. MRI images showed finding suggestive of spinal subdural hematoma at D3-D4 level producing cord compression.T1W images showed hyperintense lesion suggestive of hematoma. Initial blood work up including a complete blood count and coagulation profile yielded normal results.
Patient was treated conservatively with bedrest and steroid therapy with regular assessment of neurological functions. Later, patient showed improvement in neurological functions until she lost to follow up.

Fig 1: Magnetic resonance imaging (MRI T1W) sagittal section of whole spinal cord showing hyperintense lesion suggestive of hematoma

Fig 2: Magnetic resonance imaging (MRI T2W) sagittal section of whole spine showing heterogenous signal intensity.

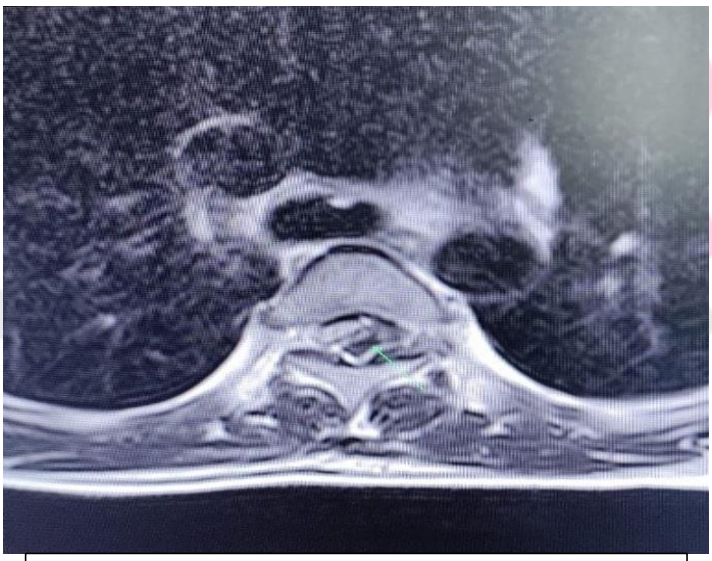

Fig 3: Magnetic resonance imaging (MRI) transverse section at D3-D4 shows right anterolateral compressive changes suggestive of reduced canal diameter.

Discussion:

Spinal subdural hematoma brings about devastating neurological dysfunction with significant morbidity and mortality. MRI is the standard modality in the evaluation of spinal cord injuries visualising not only the hematoma but also other spinal cord pathologies. Also, MRI accurately estimates the size, location and extension of the lesion.

The onset is typically acute, with an onset of sudden back pain followed quickly by signs of cord compression. Complete and permanent neurologic deficits can occur; death has also been reported rarely. The extent of the symptoms is typically dependent on the spinal level and degree of compression.

A spinal injury can cause sensory and motor deficits, and the presentation depends on the involved part of the spinal cord. Various mechanisms of spinal cord involvement may include trauma, abscess formation, tumor or compression by a hematoma [2].

Regardless of its cause, bleeding around the spinal cord can produce spinal cord compression, which can present with various symptoms depending on the site and the area involved. Sensory, motor, and autonomic functions of the spinal cord can be affected [3], and the diagnosis is made accordingly to the patterns of presentation [4].
Subdural spinal hematoma can have various causes, including arteriovenous malformation, use of anticoagulation medications, and trauma [5]. In some cases, it can spontaneously occur in the absence of any pathology [6–8], as happened in this case. Motor recovery, even if slight, could be a predictor of successful conservative therapy.

Conclusion:

Spontaneous spinal subdural hematoma can occur without any known pathology or remarkable trauma. It can cause compression of the spinal cord and should be ruled out in any patient presenting with neurological dysfunction. It can be early diagnosed with the help of MRI and early initiation of conservative treatment improves the prognosis of patient**.**

References:
1. Domoto et al. JA Clinical Reports (2018) 4:18 DOI 10.1186/s40981-018-0151-8

2.Donnally CJ III, Hanna A, Odom CK: Cervical myelopathy.In: StatPearls [Internet]. Treasure Island (FL): StatPearls Publishing; Available from: *https://www.ncbi.nlm.nih.gov/books/NBK482312/*

3. Tamburrelli FC, Meluzio MC, Masci G et al: Etiopathogenesis of traumatic spinal epidural hematoma. Neurospine, 2018; 15(1): 101–7

4.Mariano R, Flanagan EP, Weinshenker BG, Palace J: A practical approach to the diagnosis of spinal cord lesions. Pract Neurol, 2018; 18: 187–200

5. De Beer MH, Eysink Smeets MM, Koppen H: Spontaneous spinal subdural hematoma. Neurologist, 2017; 22(1): 34–3

6.Matsumoto H, Miki T, Miyaji Y et al: Spontaneous spinal epidural hematoma with hemiparesis mimicking acute cerebral infarction: Two case reports. J Spinal Cord Med, 2012; 35(4): 262–66

7. Motamedi M, Baratloo A, Majidi A et al: Spontaneous spinal epidural hematoma; A case report. Emerg (Tehran), 2014; 2(4): 183–85.

8. Kyriakides AE, Lalam RK, El Masry WS: Acute spontaneous spinal subdural hematoma presenting as paraplegia: A rare case. Spine (Phila Pa 1976), 2007; 32(21): E619–22