IJNRD.ORG ISSN : 2456-4184
INTERNATIONAL JOURNAL OF NOVEL RESEARCH AND DEVELOPMENT (IJNRD) | IJNRD.ORG
An International Open Access, Peer-reviewed, Refereed Journal

ANTIBACTERIAL ACTIVITY OF SAND CRAB (EMERITA ASIATICA) HEMOLYMPH AGAINST ASIAN SEABASS (LATES CALCARIFER) INFECTED WITH AEROMONAS SALMONICIDA

F.S. Fazil Ahamed[1], Kundan Basu[2], Ragunathan M.G[3], Jayanthi.J[*4]

Research Scholar, Research Scholar, Associate Professor, Associate Professor & Head

Department of Advanced Zoology and Biotechnology

Guru Nanak College (Autonomous), Chennai – 600042, Tamil Nadu, India.

ABSTRACT

In the current study, crude hemolymph of sand crab (*Emerita asiatica*) was used to immunize Asian seabass larvae against *Aeromonas salmonicida* infection. The bacteria isolated from the infected fish was provisionally identified as *A. salmonicida* using its biological, biochemical, physiological and structural characteristics. The study of the 16S rRNA gene using PCR provided additional confirmation. Hemolymph was extracted from the hemocoel of the *E. asiatica* crab and was tested for its anti-bacterial function using the well diffusion method. A group of fishes (Asian seabass) were treated with the hemolymph of *E. asiatica* and then challenged with the bacteria after the fourth day of booster. The Hemolymph exhibited inhibition zones ranging from 0.6 cm to 3.33 cm diameter. It was noted that the Relative Percentage Survival (RPS) was 80% against the bacteria. To examine the structural alterations in various organs, including the kidney, liver, gill, and muscles, histopathological examination was done on healthy control, experimentally infected fish, and treated larvae. The infected gill showed clubbing and lamellar fusion. The infected kidney exhibited leucocyte infiltration, tubular breakdown, and hemorrhage. Infected liver cells exhibited severe hepatic sinusoidal congestion, necrosis, and internal hemorrhage. Multiple muscle filaments were broken up in the muscle cells. The fish that had been treated showed significantly less symptoms and suffered less cellular organ damage, confirming the hemolymph's antibacterial properties. As a result, the current study proved that *E. Asiatica*'s haemolymph is a potential source of powerful antibacterial compounds and can be used as an easily accessible natural immunostimulator to fight against bacterial infections.

IndexTerms : Antibacterial activity, hemolymph, *Emerita asiatica*, *Aeromonas salmonicida*, *Lates calcarifer*, histopathology.

INTRODUCTION

The Asian seabass (*Lates calcarifer*) is a euryhaline carnivore that is raised all year round in ponds or floating cages, making it a potential choice for aquaculture in South East Asia, especially Malaysia (Anil *et al*., 2010; Jerry, 2014). Due to its financial benefits, Asian seabass cage farms are growing in popularity among marine species (FAO, 2015; Yap *et al*., 2005). With a growing demand as a preferred seafood dish in many European and North American nations, Asian seabass aquaculture is becoming a fast growing industry (Harrison *et al*., 2014). In recent decades, the output of this species has increased dramatically worldwide, and it is projected that this trend will continue (FAO, 2018). The rising demand for sea bass has resulted in a more intensive culture and, as a result, higher chances of disease breakout.

Fish diseases are the widespread issues that effects both freshwater fishes and marine fishes as well as feral, cultured, sport, and ornamental fishes. Since incredibly huge numbers of fish can succumb to disease and die under these circumstances, the issue is of paramount relevance when fishes are exposed to intensive culture practices (Trust. T J, 1986).

Vibriosis, Columnaris, and *Aeromonas* infestations are among the most prevalent bacterial infections. *A. salmonicida* is a common, facultatively anaerobic Gram-negative bacterium (Jin *et al*., 2020). These microorganisms are typical occupants of freshwater, estuaries, marine, and sediment-dwelling aquatic habitats (Swann and White, 1991). It affects both freshwater and marine fishes and is one of the earliest recorded bacterial fish pathogens. Until now, *A. salmonicida* infection has been recorded in Rainbow trout (*Oncorhynchus mykiss*), Carp (*Cyprinus carpio*), Turbot (*Scophthalmus maximus L.*), Atlantic salmon (*Salmo salar*), and Goldfish (*Carassius auratus*) (Findlay and Tatner, 1996; Coscelli *et al*., 2015; Hoover *et al*., 1998; Nakayama *et al*.,

2017; Long *et al*., 2015; Connors *et al*., 2019). Furunculosis caused by *A. salmonicida* has been a major cause of farmed fish deaths globally and is a primary factor why antibiotics are used in the aquaculture sector (Braden *et al*., 2019). Darkened skin, melanomas, appetite loss, lethargic behavior, and bleeding at the bases of the fins are signs of this disease in fish (Dallaire-Dufresne *et al*., 2014).

In aquaculture, antibiotics are typically supplied as a dietary supplement into the water, causing the medication and its metabolites to be released into the effluent (Romero *et al*., 2012). Even when antibiotic concentration levels are significantly under the minimal inhibitory concentration, the persistent presence of antibiotics in the water, combined with high bacterial counts in poly bacterial matrices like ponds, sediments, or biofilms, may exert selective pressure on bacterial populations and facilitate the transfer of antimicrobial resistance genes between bacteria (Baquero *et al*., 2008; Muziasari *et al*., 2016; Watts *et al*., 2017). The transmission of drug-resistant infections is becoming more and more likely due to the transfer of antimicrobial remnant, antibiotic resistant bacteria, and resistance genes from aquatic species and their habitat to land animals and human beings (Rasul and Majumdar, 2017; Santos and Ramos, 2018).

It has been widely believed that crustaceans have peptide defenses against microbes. In 1972, *Homarus americanus* lobster plasma (Stewart and Zwicker, 1972) and hepatopancreas (Rameshkumar *et al*., 2009) were found to have antibacterial properties. Antimicrobial compounds found in the blood cells plasma, along with manifestations like the coagulation of hemolymph or melanization, are characteristics of humoral immunity in marine invertebrates (Miyata *et al*., 1989). Bioactive elements such complement, lectins, coagulation factors, and antimicrobial peptides are present in the hemolymph of marine crustaceans (Veeruraj *et al*., 2008). Since no suitable studies on the antibacterial activity of the *E. asiatica* have been undertaken, it is necessary to adequately analyze the hemolymph of the Sand crab in order to find bioactive compounds. Thus, the aim of the current work is to find additional effective solutions with little side effects in order to reduce the harm that antibiotics produce. In this study, we challenged the Asian seabass larvae with bacteria *A. sal monicida* after injecting sand crab's (*E. asiatica*) hemolymph into them, to observe the antibacterial effects of crab hemolymph on the bacteria.

MATERIALS AND METHODS

Experimental animal collection:

Asian seabass (*L. calcarifer*) larvae (DPH-14), (average size and weight 0.7±0.1 cm and 0.004±0.002 gm) were collected from ICAR - Central Institute of Brackish water Aquaculture, Muttukadu.

The Sand Crabs, *E. asiatica* were collected from the Injambakkam coastline (130 061 N, 800 241 E,), ECR, Chennai-600115, Tamil Nadu, India. The Sand Crab had a mean weight of 15g.

Bacterial isolation and identification:

From the Aquatic Animal Health Laboratory at C. Abdul Hakeem College, Tamil Nadu, the pure strain of *A. salmonicida* was obtained. Additionally Gram staining, Catalase, Oxidase, Motility Test, Hemolysis, and PCR utilizing particular primer sets were used to confirm the bacterial strain. The media that were used for isolation includes TCBS (Thiosulphate citrate bile salt) Agar, Blood Agar, SCDA Agar, Nutrient Agar, Nutrient Broth and Mueller Hinton Agar Medium.

16S rRNA gene of *A. salmonicida* analysis by PCRn:

CTAB method for Bacterial Genomic DNA Extraction:

The CTAB technique by William *et al*. (2012) was followed.

PCR-based 16S rRNA gene amplification:

In order to amplify the gene that codes for 16S ribosomal RNA (16S rRNA) gene, which is found in *A. salmonicida*, Polymerase chain reaction (PCR) was employed with a set of particular primers that were created on the basis of nucleotide sequence of *A. salmonicida* (Singh *et al*., 2012). The primer sequence and annealing temperatures are listed in Table 1. The PCR parameters that were optimised are listed in Table 2.

Table 1. Primers for the detection of *A. salmonicida* 16S rRNA.

Primer	Product size	Sequence (5'-3')	Annealing temperature
16S rRNA F		GGC TGA TCT CTT CAT CCT CAC CCC	
16S rRNA R	421bp	CAG AGT GAA ATC TAC CAG CGG TGC	58 ºC

Table 2. Optimised PCR conditions for amplification of *A. salmonicida* 16s rRNA.

PCR parameters	Temperature (ºC)	Time
i) Denaturation	95 ºC	5 minutes
ii) 30 cycles of		
Denaturation	95 ºC	40 seconds
Annealing	58 ºC	40 seconds
Elongation	72 ºC	50 seconds
iii) Final Extension	72 ºC	10 minutes

Hemolymph collection:

3-5 animals were used to collect hemolymph from the crabs' hemocoel by passing a sterilized 2 ml syringe through the arthroidal membrane. The hemolymph was then pooled to a final volume of 2 ml. Collecting the hemolymph required the use of an anticoagulant, thus ice-cold citrate EDTA buffer was used. This was done to stop the haemocytes from degranulating and clotting (Sumalatha *et al*., 2016).

Antibacterial activity:

Well diffusion method

To find out whether plant or microbial extracts have antibacterial properties, the agar well diffusion test is frequently employed (Chavez-Esquivel *et al*., 2021). In this study, the broth culture inoculum was applied using a sterile cotton swab. After that, the cotton swab was rotated by pressing against the tube's interior wall above the fluid level in order to remove additional inoculum. *A. salmonicida* was introduced in the culture media. To inoculate the plate's agar surface swabs were used three times, each time rotating the plate by 60 degrees. The inoculum was covered with the petri dish cover and let to dry for 5 to 10 minutes at room temperature. Five wells of 8 mm in diameter were cut into the agar on plate using a sterile well cutter. Each well received 100 µl of *E. asiatica* haemolymph, with varying concentrations of 5, 10, 15, and 20 µl. 100 µl of saline solution was introduced to the other well. 2 hours were given for the solutions to diffuse. For 24-48 hours, the plates were incubated at 28 °C. By measuring the zone of inhibition surrounding the well, the antibacterial activity was determined.

Experimental Setup:

The fishes were kept in 5-liter plastic tanks filled with fresh water which was continuously aerated at room temperature (28–29 ºC). Throughout the studies, the water was provided with mild aeration without affecting the creatures. Prior to usage, air stones and air tubes were cleaned thoroughly with sterile tap water after being disinfected in 2.6% sodium hypochlorite.

Hemolymph immunization:

One group of fishes were treated with two doses of crude hemolymph of *E. asiatica*. This group was named as the immunized batch. 1 ml of crude hemolymph was used per litre of water in the tank. The first dose was given on day 1 and another subsequent booster dose on day 4. A control group was also maintained under similar conditions without any immunization. The positive control group was maintained at a safe distance to prevent uncontrolled bacterial transmission. Three replications of the tests were conducted.

Bacterial challenge:

After the fourth day of booster, the treated and untreated Asian seabass larvae were exposed to bacteria using immersion method infection (Yamamoto *et al*., 2010). Cohabitation fries of size 0.004±0.002 g was selected for experimentation. 20 Asian seabass larvae were introduced in 3 litre of freshwater in tanks with constant aeration for the immersion challenge. Polythene sheets were placed over the tanks to protect them from contamination. For the immersion technique of infection, 3 liters of water that served as the larvae's rearing medium was infused with 1 ml of a bacterial sample. To the control, 1ml of sterilized freshwater was added. Three replicates of each concentration and control were conducted. Animals were inspected two times a day for clinical illness symptoms and death. Dead animals were taken out. Three groups were made from the larvae (untreated, treated, and normal fish): group I used as a positive control, group II as an immersion challenge, and group III as a normal control group. In each batch, three replicates were utilized. All three groups were challenged with the overnight suspension of 1.15×10^9 CFU/ml. Differences in mortality were tested for statistical significance and the Relative Percentage Survival (RPS) was computed.

Histopathological investigation of Asian seabass fry:

The kidney, liver, gills, and muscles of Asian seabass larvae that had been experimentally infected with the disease were dissected out for histological analysis. For the fixation of the dissected organs, 10% neutral buffered formalin (NBF) fixative was used. Shortly, the fixed tissues were embedded in paraffin wax, sliced into 5 µm thick sections, deparaffinized in xylene, and rehydrated in a set of ethanol, in accordance with a standard methodology as explained in earlier studies (Ma *et al*., 2016). A Carl Zeiss binocular compound microscope was used to study the histological sections.

RESULT

Biochemical analysis:

The Enzyme oxidase and catalase was produced by *A. salmonicida*, and it was motile bacteria.

Table 3. Biochemical Analysis of *A. salmonicida*

Test Analysis	Bacteria – *A. salmonicida*
Motility	+
Catalase	+
Oxidase	+
Hemolysis	+

PCR Document:

By employing PCR analysis and also utilizing primers specific to bacteria, the *A. salmonicida* was confirmed and the result shown in Fig 1. The result demonstrated that for positive samples, prominent bands of PCR amplified product (421 bp) were appeared, whereas in negative control none of the equivalent band was seen.

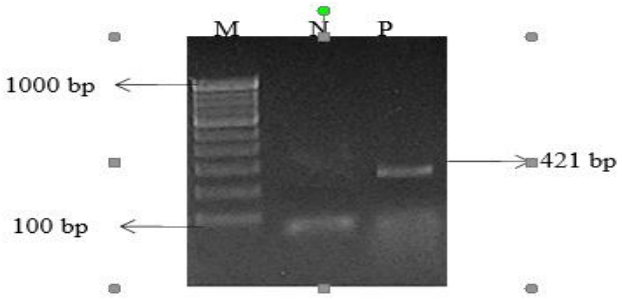

Fig. 1 Confirmation of *A. salmonicida* by PCR utilized in current investigation employing bacterial specific primer set. Lane – M 100 DNA marker; Lane N – Negative control, Lane P – Inoculum of *A. salmonicida.*

Zone of inhibition:

Table 4. Mean inhibition zones (mm) of Hemolymph (sand crab) against *A. salmonicida* at various concentrations.

Sl.no	Name of the Sample	Against *A. salmonicida*					
		5 µg	10 µg	15 µg	20 µg	25 µg	P.C
1.	Hemolymph	0.6cm	0.66cm	0.88cm	1.1m	3.33cm	6.54cm

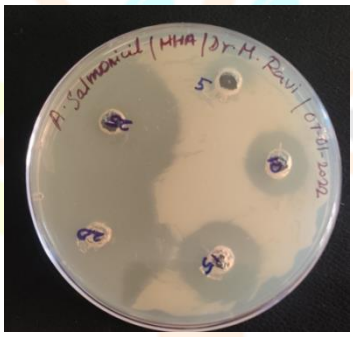

Fig. 2 Growth inhibition of *A. salmonicida*

Pathogenicity symptoms:

A. salmonicida challenged Asian seabass larvae displayed sluggishness and unusual behaviors such as bottom-resting, swimming vertically, and meandering around corners. The diseased Asian seabass larvae showed symptoms such as skin ulcer seen in dorsal side, lesions on the body surface, and rough skin were found. The ulcerative lesions were observed commonly with black spots on the opercular surface. Eyes were bulged and reddish in color. Infected Asian seabass larvae were found to exhibit these symptoms in the experimental tank. A small amount of body fouling was also seen in deceased fishes. In the pathogenicity investigation, 100% death was observed.

Fig. 3 Infected Asian seabass larvae.

Evaluation of Pathogenicity through immersion:

The duration of observation was 9 days post-infection (dpi). Mortality data showed that the fries were chronically susceptible, and impacts were seen as early as 2 dpi. Maximum death was seen between the 5th and 8th dpi, and the cumulative mortality was chronic.

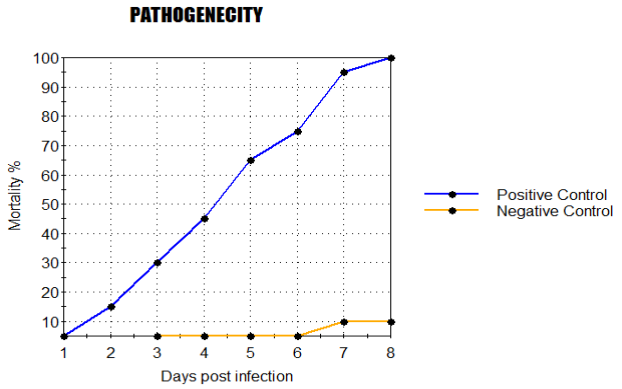

Fig. 4 Pathogenicity graph

Challenge study:

At 9 dpi with the bacterium, cumulative mortality in the untreated fish larvae was 100%. The overall death in the treated fish group was found to be 20%. The value of RPS is given in Table 5. The result indicated that hemolymph treatment was effective against *A. salmonicida* infection in Asian seabass larvae.

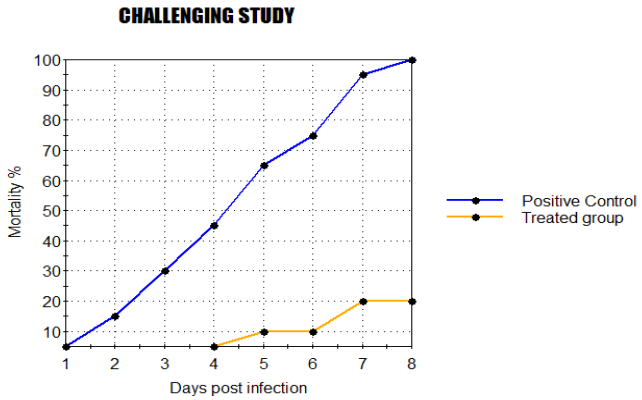

Fig. 5 Challenging study graph.

Table 5. Relative Percentage Survival (RPS) of treated fishes

Fish immersed with *A. salmonicida*	Cumulative % mortality (Total Dead/ infected fish)	Relative Percentage Survival (RPS)
Negative Control	**10% (2/20)**	**-**
Positive Control	**100% (20/20)**	**-**
Treated fish	**20% (4/20)**	**80%**

Histopathology results of Asian seabass (*L. calcarifer*) against *A. salmonicida*:

GILL:

Gills of the control Asian sea bass displayed typical lamellar epithelial arrangement. Infected gills displayed lamellar fusion and distal lamellar clubbing, hyperplasia of the basal region, infiltration of leucocytes. The treated gill lamellae mostly showed normal level of organization. Only minor degeneration was observed (Fig. 5).

KIDNEY:

Kidney of control Asian seabass exhibited typical structure and the glomeruli, hematopoietic tissue, and renal tubules were all positioned normally. Infected kidney showed tubular disintegration, infiltration of leucocytes and hemorrhage. In the treated kidney mild hemorrhage and tubular disintegration was observed (Fig. 6).

LIVER:

The liver of the control Asian seabass showed typical arrangement of all the hepatocytes. No internal hemorrhage found. Infected liver showed severe hepatic sinusoidal congestion, eosinophilic nuclear inclusions, hepatic hemorrhage, necrosis, infiltration of leucocytes. In the treated liver no hepatic congestion was observed. Extremely mild haemorrhage and necrosis was observed (Fig. 7).

MUSCLE:

The muscles of the control Asian seabass displayed the proper alignment of the muscle bundles. Absence of melanisation and necrosis. Infected muscles displayed the melanized area, leucocyte infiltration and disrupted muscle bundles. Treated muscles showed mild disruption of muscle bundles along with mild melanisation (Fig. 8).

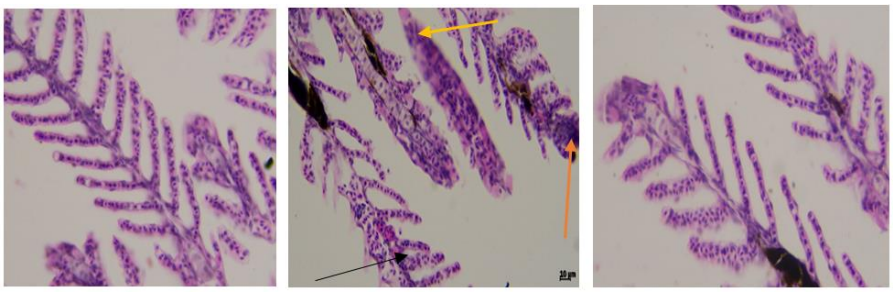

(a) **(b)** **(c)**

Fig. 6 Photomicrograph showing the Histology of Asian seabass - Gill stained with Hematoxylin & Eosin. magnification 40X. (a) Normal gill. **(**b) Infected gill, lamellar fusion and distal lamellar clubbing (Solid black arrow), hyperplasia of the basal region (yellow arrow) and infiltration of leucocytes (orange arrow). (c) Treated gill.

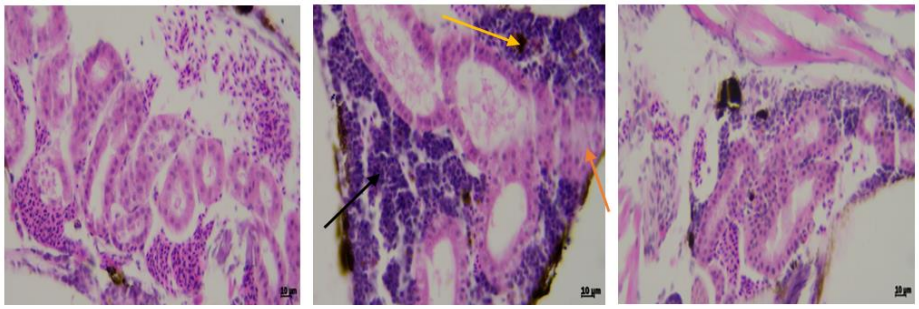

(a) **(b)** **(c)**

Fig. 7 Photomicrograph showing the Histology Asian seabass - Kidney stained with Hematoxylin & Eosin. magnification 40X. (a) Normal Kidney. **(**b) Infected kidney, tubular disintegration (Orrange arrow), infiltration of leucocytes (solid black arrow) and hemorrhage (yellow arrow). (c) Treated kidney.

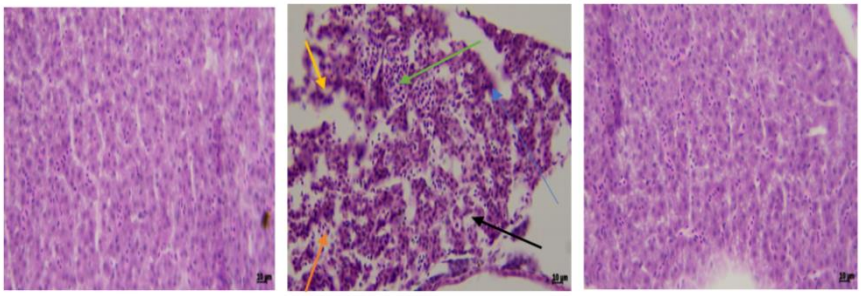

(a) **(b)** **(c)**

Figure. 8 Photomicrograph showing the Histology Asian seabass - Liver stained with Hematoxylin & Eosin. magnification 40X. (a) Normal liver. **(**b) Infected liver, severe hepatic sinusoidal congestion (Solid black arrow), eosinophilic nuclear inclusions (orange arrow), hepatic hemorrhage (blue arrow), necrosis (yellow arrow) and infiltration of leucocytes (green arrow). (c) Treated liver.

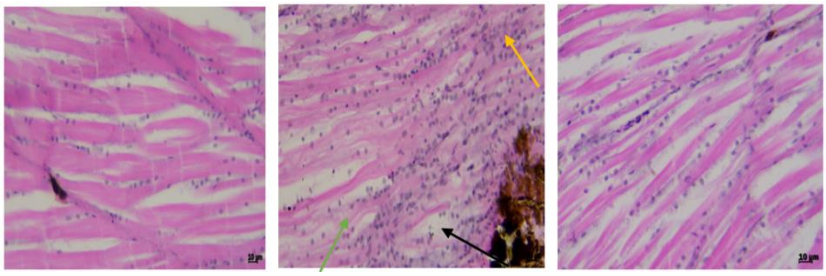

(a) **(b)** **(c)**

Fig. 9 Photomicrograph showing the Histology Asian seabass - Muscle stained with Hematoxylin & Eosin. magnification 40X. (a) Normal muscle. **(**b) Infected muscle, melanized area (Solid black arrow), leucocyte infiltration (yellow arrow) and disrupted muscle bundles (green arrow). (c) Treated muscle.

DISCUSSION

Many crustacean physiologists have paid close attention to the hemolymph of decapods because of the great range of diversity seen in its contents. Proteins in crustacean hemolymph vary depending on nutritional status and bioactivity. Due to their potential for pharmaceutical use, research into the bioactivity of natural compounds has received a lot of interest recently (Sumalatha *et al*., 2016).

In this current work, Asian seabass larvae were immunized against *A. salmonicida* infection using crude hemolymph of sand crab (*E. asiatica*). Both in-vitro and in-vivo investigations using the crude hemolymph of *E. asiatica* revealed considerable antibacterial activity. RPS value of 80% was noted against the bacteria in the challenge study with Asian seabass larvae. The findings clearly demonstrated the degree of efficacy of sand crab's haemolymph against *A. salmonicida*. The hemolymph not only strengthened the larvae's defenses against bacterial pathogens but also accelerated the larval development phase in Asian seabass. The treated group larvae were much bigger and entered their next phase of development well ahead of the positive control group. An in-depth analysis of the subject might provide a clear perspective.

Similar to the current study, several earlier investigations into the antibacterial activities of various crab species have also been conducted. The antimicrobial properties of mud crabs which are belongs to the genus *Scylla* have recently undergone

extensive study and have been documented in several studies (Velayutham and Munusamy, 2016; Pandey *et al*., 2010; Sperstad *et al*., 2011; Hoq *et al*., 2003; Fredrick and Ravichandran, 2012). In a more recent work, Velayutham and Munusamy (2016) examined the humoral immunological activity of hemocyanins that had been extracted from the serum of mud crab, *Scylla* serrata. According to the reports, hemocyanin has an immunological activity that can guard against potential illnesses in the aquaculture sector. By Sivaperumal *et al*. (2013), a new peptide from the hemolymph of the crab *Ocypode macrocera* was identified and demonstrated dual characteristics, including antibacterial action and antioxidant activity. In the investigation of Hoq *et al*. (2003), *Escherichia coli* was injected into *S. serrata* hemolymph to examine the presence of constitutive and induced antimicrobial proteins. The findings revealed that when tested against *Bacillus megaterium*, *Bacillus cereus*, *Bacillus subtilis*, *Streptococcus pyogenes*, and S*taphylococcus aureus*, the induced hemolymph of mud crab, as determined by disk diffusion method, was found to contain a considerable antibacterial effect.

CONCLUSION

Haemorrhagic disease outbreaks caused by *Aeromonas* have a high fatality rate. Common treatment includes antibiotics, however their over usage permanently harms the ecosystem. As a result, alternative methods of disease control are required. The present study can be expanded upon by isolating the bioactive substances that are essential to the anti-microbial activity of sand crab hemolymph. If the compound is properly purified, it may very likely replace traditional antibiotics. Thus, eradicating pathogens that are resistant to drugs.

ACKNOWLEDGEMENT

We sincerely acknowledge the ICAR - Central Institute of Brackish water Aquaculture, Muttukadu for supplying the Asian Seabass larvae for the present study. The authors also extend their gratitude to Sardar Manjit Singh Nayar, General Secretary and Correspondent of Guru Nanak College (Autonomous), Chennai, Tamil Nadu, India, for his unwavering support.

CONFLICT OF INTEREST

The authors declare no competing interests.

REFERENCES

[1] Anil, M. K., Santhosh, B., Jasmine, S., Saleela, K. N., George, R. M., Jose Kingsly, H., & Syda Rao, G. 2010. Growth performance of the sea- bass Lates calcarifer (Blotch) in sea cage at Vizhinjam Bay along the south-west coast of India. Indian Journal of Fisheries, 57(4): 65–69.

[2] Baquero, F., Martínez, J. L., & Cantón, R. 2008. Antibiotics and antibiotic resistance in water environments. Current opinion in biotechnology, 19(3): 260-265.

[3] Braden, L. M., Whyte, S. K., Brown, A. B., Iderstine, C. V., Letendre, C., Groman, D., ... & Fast, M. D. 2019. Vaccine-induced protection against furunculosis involves pre-emptive priming of humoral immunity in Arctic charr. Frontiers in immunology, 10: 120.

[4] Chavez-Esquivel, G., Cervantes-Cuevas, H., Ybieta-Olvera, L. F., Briones, M. C., Acosta, D., & Cabello, J. 2021. Antimicrobial activity of graphite oxide doped with silver against Bacillus subtilis, Candida albicans, Escherichia coli, and Staphylococcus aureus by agar well diffusion test: Synthesis and characterization. Materials Science and Engineering: C, 123: 111934.

[5] Connors, E., Soto-Dávila, M., Hossain, A., Vasquez, I., Gnanagobal, H., & Santander, J. 2019. Identification and validation of reliable Aeromonas salmonicida subspecies salmonicida reference genes for differential gene expression analyses. Infection, Genetics and Evolution, 73: 314-321.

[6] Coscelli, G. A., Bermúdez, R., Losada, A. P., Santos, Y., & Quiroga, M. I. 2015. Vaccination against Aeromonas salmonicida in turbot (Scophthalmus maximus L.): study of the efficacy, morphological changes and antigen distribution. Aquaculture, 445: 22-32.

[7] Dallaire-Dufresne, S., Tanaka, K. H., Trudel, M. V., Lafaille, A., & Charette, S. J. 2014. Virulence, genomic features, and plasticity of Aeromonas salmonicida subsp. salmonicida, the causative agent of fish furunculosis. Veterinary microbiology, 169(1-2): 1-7.

[8] FAO 2015. Characteristics, structure and resources of the sector. FAO Cauntry Notes, (1380): 1–16.

[9] FAO, 2018. Fishstat Plus Version 2.30. Food and Agricultural Organization Fisheries Department, Fishery information, Data and Statistics Unit.http://www.fao.org./fi/statist/FISOFT/FISHPLUS (accessed 17 December 2018).

[10] FINDLAY, C., & TATNER, M. F. 1996. The effect of reconstitution with cryopreserved thymocytes on thein vivoantibody response to sheep red blood cells, Aeromonas salmonicida, and DNP-KLH, in adult long term thymectomised rainbow trout (Oncorhynchus mykiss). Fish & Shellfish Immunology, 6(5): 371-381.

[11] Fredrick, W. S., & Ravichandran, S. 2012. Hemolymph proteins in marine crustaceans. Asian Pacific Journal of Tropical Biomedicine, 2(6): 496-502.

[12] Harrison, P., Calogeras, C., Philips, M., 2014. Farming of barramundi/Asian seabass: an Australian industry perspective. In: Jerry, D.R. (Ed.) Biology and Culture of Asian Seabass Lates calcarifer. CRC Press, Boca Raton, USA. 225 pp.

[13] Hoover, G. J., El-Mowafi, A., Simko, E., Kocal, T. E., Ferguson, H. W., & Hayes, M. A. 1998. Plasma proteins of rainbow trout (Oncorhynchus mykiss) isolated by binding to lipopolysaccharide from Aeromonas salmonicida. Comparative Biochemistry and physiology part B: biochemistry and molecular biology, 120(3): 559-569.

[14] Hoq, M. I., Seraj, M. U., & Chowdhury, S. 2003. Isolation and Characterization of Antibacterial Peptides from the Mud-crab, Scyllaserrata.

[15] Jerry, D. R. (Ed.) 2014. Biology and culture of Asian Seabass Lates cal- carifer (1st ed.). Boca Raton, FL: CRC Press, Taylor & Francis Group.

[16] Jin, S., Fu, S., Li, R., Dang, H., Gao, D., Ye, S., & Jiang, Z. 2020. Identification and histopathological and pathogenicity analysis of Aeromonas salmonicida from goldfish (Carassius auratus) in North China. Aquaculture and Fisheries, 5(1): 36-41.

[17] Long, M., Zhao, J., Li, T., Tafalla, C., Zhang, Q., Wang, X., ... & Li, A. 2015. Transcriptomic and proteomic analyses of splenic immune mechanisms of rainbow trout (Oncorhynchus mykiss) infected by Aeromonas salmonicida subsp. salmonicida. Journal of proteomics, 122: 41-54.

[18] Ma, H., Peng, C., Su, Y., Feng, J., & Guo, Z. 2016. Isolation of a Ranavirus-type grouper iridovirus in mainland China and comparison of its pathogenicity with that of a Megalocytivirus-type grouper iridovirus. Aquaculture, 463: 145-151.

[19] Miyata, T., Tokunaga, F., Yoneya, T., Yoshikawa, K., Iwanaga, S., Niwa, M., ... & Shimonishi, Y. 1989. Antimicrobial peptides, isolated from horseshoe crab hemocytes, tachyplesin II, and polyphemusins I and II: chemical structures and biological activity. The Journal of Biochemistry, 106(4): 663-668.

[20] Muziasari, W. I., Pärnänen, K., Johnson, T. A., Lyra, C., Karkman, A., Stedtfeld, R. D., ... & Virta, M. 2016. Aquaculture changes the profile of antibiotic resistance and mobile genetic element associated genes in Baltic Sea sediments. FEMS microbiology ecology, 92(4), fiw052.

[21] Nakayama, K., Yamashita, R., & Kitamura, S. I. 2017. Use of common carp (Cyprinus carpio) and Aeromonas salmonicida for detection of immunomodulatory effects of chemicals on fish. Marine Pollution Bulletin, 124(2): 710-713.

[22] Pandey, A., Naik, M., & Dubey, S. K. 2010. Hemolysin, protease, and EPS producing pathogenic Aeromonas hydrophila strain An4 shows antibacterial activity against marine bacterial fish pathogens. Journal of Marine Biology, 2010.

[23] Rameshkumar, G., Aravindhan, T., & Ravichandran, S. 2009. Antimicrobial proteins from the crab Charybdis lucifera (Fabricius, 1798). Middle-East Journal of Scientific Research, 4(1): 40-43.

[24] Rasul, M. G., & Majumdar, B. C. 2017. Abuse of antibiotics in aquaculture and it's effects on human, aquatic animal and environment. The Saudi Journal of Life Sciences, 2(3): 81-88.

[25] Romero, J., Feijoó, C. G., & Navarrete, P. 2012. Antibiotics in aquaculture–use, abuse and alternatives. Health and environment in aquaculture, 159: 159-198.

[26] Santos, L., & Ramos, F. 2018. Antimicrobial resistance in aquaculture: current knowledge and alternatives to tackle the problem. International Journal of Antimicrobial Agents, 52(2): 135-143.

[27] Singh, V., Chaudhary, D. K., & Mani, I. 2012. Molecular characterization and modeling of secondary structure of 16S rRNA from Aeromonas veronii. Int J Appl Biol Pharm Technol, 3(1): 253-260.

[28] Sivaperumal, P., Kamala, K., Natarajan, E., & Dilipan, E. 2013. Antimicrobial peptide from crab haemolymph of Ocypoda macrocera (Maline Edwards 1852) with reference to antioxidant: A case study. International Journal of Pharmacy and Pharmaceutical Sciences, 5(2): 672-680.

[29] Sperstad, S. V., Haug, T., Blencke, H. M., Styrvold, O. B., Li, C., & Stensvåg, K. 2011. Antimicrobial peptides from marine invertebrates: challenges and perspectives in marine antimicrobial peptide discovery. Biotechnology advances, 29(5): 519-530.

[30] Stewart, J. E., & Zwicker, B. M. 1972. Natural and induced bactericidal activities in the hemolymph of the lobster, Homarus americanus: products of hemocyte–plasma interaction. Canadian Journal of Microbiology, 18(9): 1499-1509.

[31] Sumalatha, D., Jayanthi, J., & Ragunathan, M. G. 2016. Antioxidant property of the crude peptide extracts of a fresh water crab, Oziotelphusa senex senex. Int J Pharm Bio Sci, 7(3): 202-207.

[32] Swann, L., & White, M. R. 1991. Diagnosis and treatment of" Aeromonas hydrophila" infection of fish. Aquaculture Extension, Illinois-Indiana Sea Grant Program.

[33] Trust, T. J. 1986. Pathogenesis of infectious diseases of fish. Annual Reviews in Microbiology, 40(1): 479-502.

[34] Veeruraj, A., Ravichandran, S., & Rameshkumar, G. (2008). Antibacterial activity of crab haemolymph on clinical pathogens. Trends in Applied Sciences Research, 3(2): 174-181.

[35] Velayutham, M., & Munusamy, A. 2016. Humoral immune responses of antibacterial hemocyanin (Ab-Hcy) in mud crab, Scylla serrata. Aquaculture, 464: 428-433.

[36] Watts, J. E., Schreier, H. J., Lanska, L., & Hale, M. S. 2017. The rising tide of antimicrobial resistance in aquaculture: sources, sinks and solutions. Marine drugs, 15(6): 158.

[37] William, S., Feil, H., & Copeland, A. 2012. Bacterial genomic DNA isolation using CTAB. Sigma, 50(6876).

[38] Yamamoto, T., Kawai, K., & Oshima, S. I. 2010. Evaluation of an experimental immersion infection method with Tenacibaculum maritimum in Japanese flounder Paralichthys olivaceus. Aquaculture Science, 58(4): 481-489.

[39] Yap, W. G., Fungesmith, S., Rimmer, M., Phillips, M. J., Sim, S. Y., Kongkeo, H., & Bueno, P. B. 2005. Aquaculture in Asia-Pacific and the Outlook for mariculture in Southeast Asia in the Asia-Pacific region, (August), 1–25.