



REVIEW ON DRUG CONTAINING HYDROGEL FOR THE TREATMENT OF CONJUNCTIVITIS

¹Mr. Kale Dipak Raju* , ²Prof.Waghmare S.U, ³Miss.Rohini Kawar , ⁴Miss.vaishnavi Badak, ⁵Prof.Ram Ingle,

^{1,3,4} UG Scholar of Rashtriya College of Pharmacy Hatnoor, Tq.Kannad Dist. Chh.Sambhajinagar Maharashtra, India -431103.

^{2,5} Assistant Professor of Rashtriya College of Pharmacy Hatnoor, Tq.Kannad Dist. Chh.Sambhajinagar Maharashtra, India -431103.

²Department of Pharmaceutics ,

⁵Department of Pharmaceutical chemistry,

¹Rashtriya College of Pharmacy Hatnoor, Tq.Kannad Dist. Chh.Sambhajinagar Maharashtra, India -431103.

*Corresponding Author

Rashtriya College of Pharmacy Hatnoor, Tq.Kannad Dist. Chh.Sambhajinagar Maharashtra, India -431103*

Abstract:

This review's primary goal is to provide an overview of hydrogel-based conjunctivitis treatments. Conventional medications including eye drops can be used under the present circumstances. Conventional drug forms such as eye drops have poor therapeutic responses and require regular dosage adjustments. Therefore, the pressing issue facing medical diligence investigators is creating a drug form that would carry the medication to the intended spot without significantly depleting the drug or producing any systemic side effects. ⁽¹⁾ Around the world, conjunctivitis is a common ailment seen at ophthalmology conferences. Fearful signals have a greater number of serious intraocular disorders that need to be taken into consideration when treating presumed cases of conjunctivitis. These conditions correspond to significant pain ⁽²⁾, reduced vision and also patients with unusual anomalies and a history of eye conditions should also have an ocular examination. long-term duration. Findings from a concurrent physical examination and pertinent medical history may show involvement of the conjunctiva in an underlying illness. The definition of "hydrogel" refers to a type of polymeric compound whose hydrophilic structure allows them to retain enormous amounts of water that remain in their three-dimensional natural networks. In addition to other types of synthetic biomaterials, they remarkably resemble genuine living tissues because of they have contain large proportion of water, porosity, and soft viscosity. ⁽³⁾ To create a hydrogel that will lengthen a medicine's retention period in an ocular pharmaceutical delivery method. In order

to ensure the best possible bioavailability at the site of action, hydrogel ophthalmic doses made with HPMC have demonstrated excellent characteristics and a respectable sustained release profile. The conclusions of this investigation showed that using medications with hydrogel ophthalmic substances during eye care was effective (4)

Key Words: Conjunctivitis, Disease, Hydrogel, Ophthalmology, Haemophilia's' influenza, Ocular etc.

INTRODUCTION :

Conjunctivitis is characterized by enlargement of the circulatory system's vessels, ocular ejection, discomfort, and inflammatory processes of the conjunctival tissue. Numerous individuals worldwide suffer from conjunctivitis, which is regarded as one of the most common reasons for office visits to conferences in ophthalmology and conventional medicine. It has been stated that more than 80% of all cases of acute blindness are diagnosed by medical specialists who are not ophthalmologists, such as family physicians, internists, Pediatricians as well as registered nurses. Medical professionals, pediatrics, and advanced practice nurses. This has a significant financial impact on the healthcare industry and is the cause of many Visits to several medical specialists' offices. The yearly average cost of treating bacteria just in the United States, conjunctivitis is estimated to be \$857 million. (5)

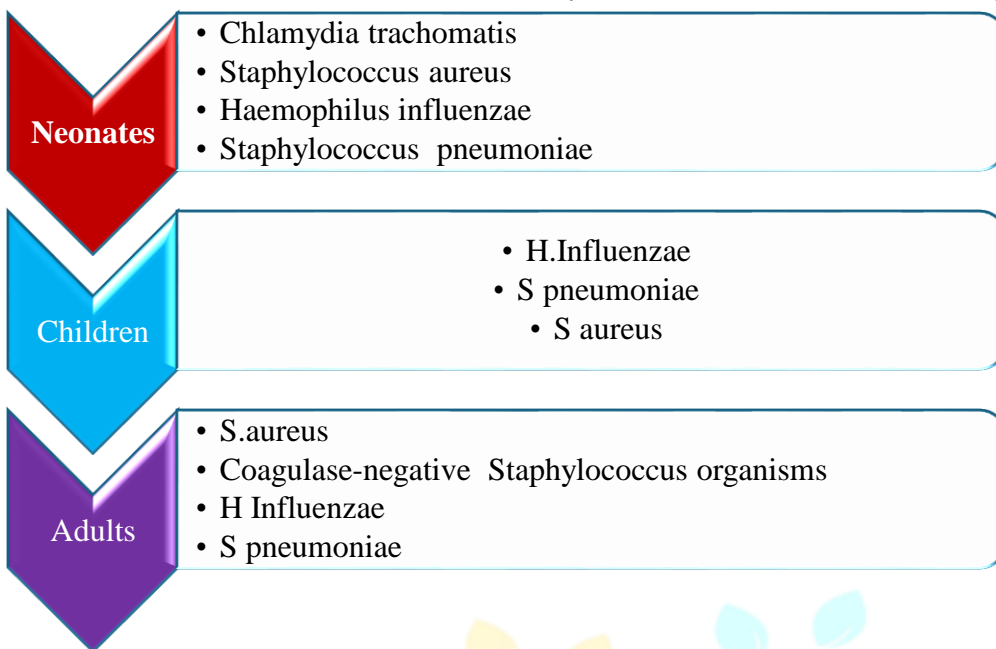
What does "hydrogel" mean? Is used to describe a class of polymeric compounds that, thanks to their hydrophilic nature, can massive volumes of water that are still present within their the 3D natural systems. Compared to other kinds of artificial biomaterials, they Ingly mimic real excruciating pupillary response .A complete medical and physical examination and a comprehensive medical and ocular history is a patient's history of eye conditions, including glaucoma, cataracts, and injuries should also be performed on patients who have atypical abnormalities and a chronic course. Simultaneous physical exam findings and relevant medical history may indicate conjunctival involvement in an underlying disease. (6)

➤ The causes of conjunctivitis are numerous:

The concept of "conjunctivitis" refers to inflammation of the conjunctiva caused by a variety of non-infectious (such as allergic, chemical, or mechanical) and infectious microorganisms (e.g., bacteria, viruses, or fungi). On the basis of the patient's age, different microorganisms usually lead to bacterial conjunctivitis

Table 1:

Common reason for bacterial conjunctivities in new borns:



Additional reasons for red eyes. Several instances neonates with red eyes often have conjunctivitis; Chlamydia trachomatis is the most frequent bacterial reason for conjunctivitis. Children delivered to elderly women with cervical chlamydial infections typically exhibit purulent unilateral or bilateral discharge approximately one week after birth, which is the typical presentation of chlamydial conjunctivitis. About 50% of neonates with chlamydial pneumonitis either have contemporaneous conjunctivitis or have had prior cases of conjunctivitis. Many new-borns with chlamydial conjunctivitis additionally develop chlamydial pneumonitis.⁽⁷⁾

One uncommon root for Neisseria gonorrhoea is neonatal conjunctivitis. This organism typically causes severe “hyper-acute” conjunctivitis with gushing precipitation in the first week of life, which can induce corneal involvement and perforation. The beginning is slightly earlier compared with chlamydial conjunctivitis. Its incidence and complications have been significantly reduced by routine preventative antibiotics at delivery. Streptococcus pneumoniae, Haemophilus influenzae or Staphylococcus aureus, however, are among other bacteria that can cause new-born conjunctivitis.⁽⁸⁾

According to a prospective investigation conducted in Israel, H influenzae or S pneumonia account for 29% and 20% of cases, respectively, of bacterial conjunctivitis in youngster it’s unclear from this study if cases had received vaccinations against H. Influenzae. Conjunctivitis caused by H. Influenzae is easily transmitted in homes and seminars. It is linked to otitis media (conjunctivitis-otitis) and concurrent upper respiratory system infections. In situations of purulent conjunctivitis, ipsilateral otitis media occurs in 45% to 73% of cases. S. Pneumoniae is a frequent source of epidemic breakouts in young adults and also the second more prevalent cause of conjunctive inflammation in children.⁽⁹⁾

S. aureus and H. Influenzae are the more commonly caused bacterial conjunctivitis in adult. S. Aureus-induced conjunctivitis frequently occurs at recurrent intervals and is linked to chronic pharconjunctivitis, which is inflammation of the conjunctiva and eyelids. S. Aureus colonises the conjunctivae in 3.8% to 6.4 percent of healthy adults. 9–11 Furthermore, 20% of people usually have S. Aureus in their nasal cavities all the time, and another 60% have it occasionally; in both situations, the bacterium may contribute to sporadic eye infections. Other organisms that commonly cause conjunctivitis in adults include Moraxella and Acinetobacter species, S pneumonia, and Coagulase-negative staphylococci.⁽¹⁰⁾

Conjunctivitis although similar symptoms can also be seen in other illnesses. A focused ophthalmologic history and physical examination are typically sufficient to detect whether a patient has a major vision-threatening disorder (e.g., acute-angle closure glaucoma, microbial keratitis, or anterior uveitis). A recommendation to an ophthalmologist for an accurate diagnosis should be made as soon as the practitioner notices any concerning clinical symptoms, such as extreme pain, difficulty seeing, or a hazy cornea in a patient with red eye syndrome (Table 2).⁽¹¹⁾

Table 2:

Variations in Red Eye Diagnosis
○ Acute glaucoma
○ Inflamed Conjunctivitis
○ Anterior uveitis
○ Blepharitis
○ Chemical Conjunctivitis
○ Dry eye
○ Episcleritis
○ Foreign body
○ Infected Conjunctivitis
○ Keratitis
○ Scleritis
○ Sub conjunctivitis haemorrhage

➤ Symptoms, Prevention, and At-Home Monitoring

I) Symptoms of Eye Conjunctivitis: The main frequent signs of conjunctivitis are eye irritation and paleness. Additional typical symptoms consist of a burning and itching feeling.

- Ocular hydration
- Light sensitivity
- Ocular discharge, which may result in encrustation and eyelid adhesion.

II) Preventing Conjunctivitis of an Eyes: The method that follows can facilitate conjunctivitis's spread.

- Practice good hygiene, particularly during the cold and flu season;
- Wash your hands frequently, especially before touch of your eyes
- Avoid touching of eyes with your hands;
- Avoid using pillows, napkins, and other personal items;
- Wear defensive eyewear when necessary, when swimming or engaging in other activities that pose a risk of eye exposure.

III) Home Care for Ocular Conjunctivitis:

While the majority of conjunctivitis patients have while the majority of conjunctivitis infections require medical attention, there are a number of at-home eye flu treatments that can reduce symptoms

- Comfortable compression applying a hot compress can help reduce irritation and inflammation. Several times a day, apply a warm compress for five to ten twinkles.
- Cold press a cold wave compress may be able to help with conjunctivitis symptoms in certain situations. Apply a fresh cloth or an ice pack covered in a kerchief to the afflicted eye and watch it glitter for five to ten minutes
- Unintentional Artificial Gashes: These can provide a temporary solution for ocular strain and blankness.
- Tidy up the eye region to get rid of any discharge from the eye gently cleans the affected region with a fresh, moist towel. Additionally, this may lessen the chance of spreading infection ⁽¹²⁾

➤ Epidemic conjunctivitis:

Several diseases have been shown to able to infect vast populations and cause infectious diseases that are either narrower or wider than anticipated. Nevertheless, conjunctivitis has historically sparked multiple pandemics and while the most of instances are benign and self-limiting, many underestimate its influence on the general public and its capacity to spread quickly. Global health systems monitor epidemic forms of conjunctivitis, particularly hemorrhagic forms. One of their primary characteristics is the quick spread and high number of cases that occur in short periods of time; they can more prevalent in the summer. Certain serotypes are widely dispersed, and they are typically the ones that have the potential to spread like an epidemic. ^(13, 14) The efficiency with which conjunctivitis can be propagated through almost all known modes of transmission (see Modes of Transmission) only partially explains the rapidity of its spread. It is well known that elevated temperatures and elevated relative humidity, which extend the life of transmission, cause severe hemorrhagic conjunctivitis in tropical regions. Additional viral environmental variables, such as those found in adenoviruses, facilitate viral establishment in unfavourable environments and are linked to pandemics. The number of incidents indicating that medical personnel are complicit in the propagation of an epidemic is steadily declining. When there are no relevant threat, the medical labour force can become a point of criticism. Adenovirus is a major source of pandemic hemorrhagic conjunctivitis cases. Nevertheless, Coxsackie A24 is currently to blame for the documented global pandemic. After being discovered for the first time in Ghana in 1969, it later extended throughout Asia and Oceania. By the end of the 20th century, there were frequent publications detailing incidents brought on by various coxsackievirus strains. ^(15, 16) This epidemic spread to several major countries, including Australia, where coxsackie A24-induced acute conjunctivitis in anon-hemorrhagic form can be found the cause. ^(17, 18) (Figure 1)

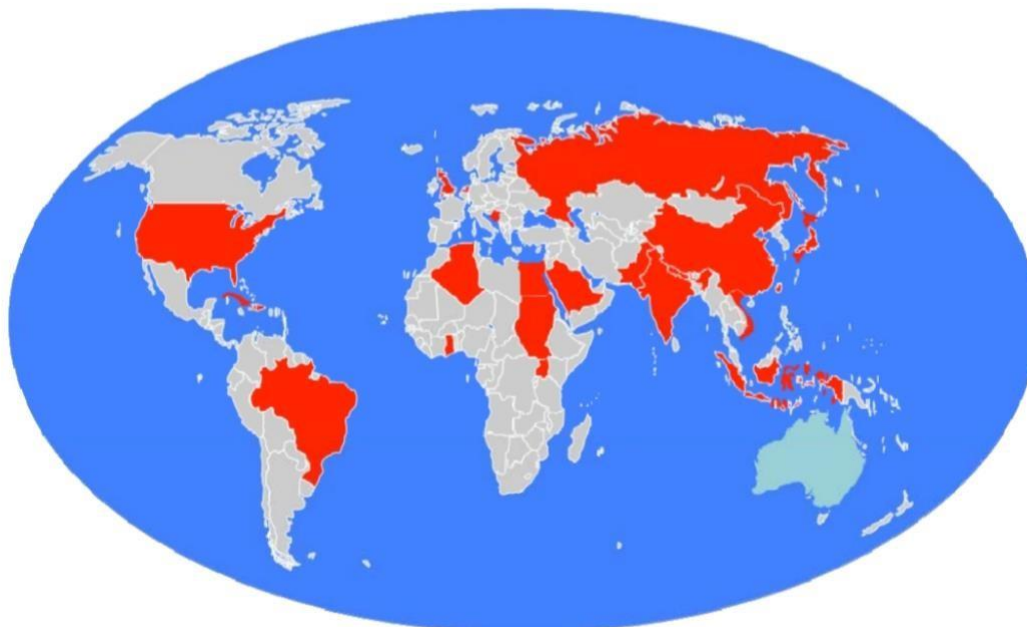


Fig.1: Spread of coxsackie A24-caused epidemic hemorrhagic conjunctivitis. The countries that were diagnosed with hemorrhagic conjunctivitis are indicated in red, whereas the non-haemorrhagic countries are indicated in blue.

➤ **Non-epidemic conjunctivitis:**

One common issue was seen in a large percentage of ophthalmologist consultations is conjunctivitis. Non-epidemic versions of this illness typically don't have the potential to affect huge populations, but they can still have an influence on medical costs, temporary impairment, and, in rare situations, the ability to contain an outbreak. Antipathetic conjunctivitis is the primary cause of non-epidemic conjunctivitis. They have also demonstrated an increase in incidence and prevalence, and collectively, they constitute the primary cause of conversation around conjunctivitis in affluent nations. Both adults and toddlers experience antagonistic conjunctivitis rather frequently. The literature reports varying estimates of its prevalence, ranging from 15 to 25 percent of the general population. ⁽¹⁹⁾ Similar to seasonal antipathetic conjunctivitis (SAC), antipathetic conjunctivitis comprises five clinical realities or classes. Atopic Keratoconjunctivitis (AKC), Vernal Keratoconjunctivitis (VKC), Impishable Antipathetic Conjunctivitis (PAC), and Giant Papillary Conjunctivitis (GPC) are the most common types of antipathetic conjunctivitis. While the AKC and VKC, which also impact the cornea, represent more severe, usually bilateral, types, the SAC and PAC are very minor kinds. The GPC doesn't show up too often. ⁽²⁰⁾ Common allergens are linked to allergic sympathetic conjunctivitis; patients frequently also have an atopy and a family history of dislike. Between the ages of 10 and 40, this form of conjunctivitis most commonly occurs, peaking in the alternating decade, time and again. The most repeatedly involved allergens are colourful inhalant allergens, similar to pollen species, dermatophagoides pteronyssinus, dermatophagoides farinae, colourful moulds (Aspergillus fumatus, Aspergillus niger, Alternaria family, Cladosporium family, Penicillium family, Candida albicans, Thermopolyspora polyspora), beast danders(hairs, feathers, squamae), organic dusts, some foods in greasepaint form(flour kinds, spices); II. Some medicines (e.g. in vanishing cream form, ointments, etc) III. Digested foods; IV. Contact allergens. ⁽²¹⁾ Certain episodes of conjunctivitis are linked to physical or chemical contaminants that are present in the workplace and pose a risk

to the patient. Mepacrine, ammonia, and vanadium are the three of these substances that most frequently result in conjunctivitis associated with the workplace. Mostly connected to the metal working sector. When it comes to physical agents, the primary cause of conjunctivitis is ultraviolet light exposure from outside jobs like construction and law enforcement. Handling infected fluids is another kind of work-related risk linked to conjunctivitis. If proper hygiene precautions are not implemented, this could pose a serious risk to the medical personnel who treat patients. The other occurrences of conjunctivitis are caused by viruses, bacteria, fungi, and parasites (nonepidemic serotypes), which are also a major contributor to the daily number of consultations with ophthalmologists. But these ought to be addressed in accordance with the underlying cause. Since these conjunctivitis kinds are primarily acquired in hospitals, they can be classified as nosocomial outbreaks (e.g. Staphylococcus sp., adenovirus, herpes virus and Candida spp., Among others)^(22, 23)

➤ CONJUNCTIVITIS TYPES:

1) Viral conjunctivitis

The primary cause of conjunctivitis that is transmissible overall is viral conjunctivitis, which often develops as a result of adenovirus implantation of the ocular surface.^(24, 25) Other viruses could be The fundamental cause less commonly. Investigations have been conducted on the viruses' in cases of the viral conjunctivitis that can be herpes simplex virus (HSV), varicella zoster virus (VZV), and enterovirus (26)

2) Adenoviral conjunctivitis.

Up to 90% of instances of conjunctive inflammation are caused by adenoviruses, making them the predominant reason of conjunctiva that is spread worldwide. (27) Fresh advancements in The sequencing of the human adenovirus (HAdV) gene has identified over 72 different HAdV genetic makeup. Seven distinct types (HAdV-A to HAdV-G) were separated out of 1, with the largest membership base and the strongest association with viral conjunctivitis were discovered in the HAdV-D species. (28, 29) Children frequently contract pharyngo conjunctival fever (PCF), which is mainly brought on by HAdV types 3, 4, and 7. (30, 31) The typical signs of this sickness are fever, pharyngitis, periauricular lymphadenopathy in and acute follicular conjunctivitis. Oedema is caused by the interaction between the conjunctival vasculature and pro-inflammatory cytokines. Hyperemia and conjunctive petechial haemorrhage's, as well as ocular surface Anomalies. (32) This corresponds to a self-limiting condition that oftentimes 14 resolves by itself in Roughly two weeks without receiving any medical attention. A visual expression of epidemic keratoconjunctivitis (EKC) is one of them. Adenovirus implantation 1 on the ocular surface is frequently the source of viral conjunctivitis, which is the primary reason of conjunctivitis that is generally transmissible. Additional viruses might be the primary reason less frequently. Exams have been conducted Carried out on the the viruses varicella (VZV), herpes simplex virus infection (HSV), and An enterovirus in situations involving conjunctivitis caused by viruses.

The development of conjunctival tissue and pseudomembrane, follicular conjunctive inflammation corneal sub epithelial infiltrates (SEI), corneal scars, conjunctival discharge, and symblepharon formation are among the ocular symptoms of EKC (Figures 2 and 3).⁽²⁹⁾

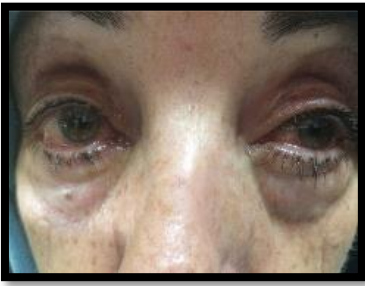

Figure 2: Bilateral watery eyes due to adenoviral conjunctivitis.

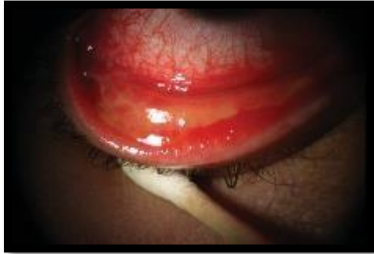

Figure 3: Adenoviral conjunctivitis patient with pseudomembrane development.

Pseudo membranes—fibrin-rich exudates without lymphatic or blood vessels—may be seen in EKC patients' tarsal conjunctiva. Conjunctival tissue may also emerge in EKC, depending on the intensity of inflammation. Once they form, true membranes might result in the can cause symblepharon and sub epithelial fibrosis to develop; they also frequently bleed profusely when removed⁽³³⁾

3) Herpetic conjunctivitis:

1.3% to 4.8% of all acute conjunctivitis cases are thought to be caused by the herpes simplex virus (HSV).^(34,35) HSV usually causes a single follicular conjunctivitis, which can be accompanied by a thin, watery discharge and vesicular damage on the surface of the eyelids. Therapy includes topical antiviral drugs like ganciclovir, idoxuridine, vidarabine, and trifluridine. The aim of herpes zoster treatment is to reduce virus shedding and the likelihood of developing keratitis. Optic involvement with the virus, especially when the first and second branches of the trigeminal nervous system are affected, can cause conjunctiva in 41.1% of cases, eyelid injuries in 45.8%, and uveitis in 32.1% of cases. Another 19.1% of cases had corneal lesions such as nummular keratitis, pseudo-dendrites, etc.^(36, 37)

4) Hemorrhagic conjunctivitis:

Acute hemorrhagic conjunctivitis (AHC) is a type of viral conjunctivitis that is particularly contagious. Its symptoms include foreign body sensation, excessive tears, edema of the eyelids, dilation of the corneal vessels, chemosis, and subconjunctival hemorrhage. Leg pain, fatigue, and fever may occur in a few patients. subtypes of adenovirus, two picornaviruses (mostly enterovirus 70 (EV70) and coxsackievirus A24 variant (CA24v)) are thought to be the culprits. AHC is thought to be mostly transmitted by hand-to-eye contact and contaminated objects, as in other types of conjunctivitis (38, 39). The disease is self-limiting, and its symptoms gradually improve during the first week of infection (6 days) and completely disappear in ten to fourteen days⁽⁴⁰⁾.

Medical intervention primarily aims to contain large outbreaks and implement preventative measures, such as frequent hand washing and limiting contact with affected individuals, to protect vulnerable groups, including children, the elderly, pregnant women, and immune compromised patients⁽³⁹⁾

5) Bacterial conjunctivitis:

Bacterial conjunctivitis is more common in children than in adults, but it is much more common in children. ⁽⁴¹⁾ Bacterial conjunctivitis can also result from an abnormal buildup of the conjunctival foliage or an initial exposure to pathogen-contaminated materials. Contaminated fomites ⁽⁴⁵⁾, oculogenital spread ⁽⁴⁴⁾, tainted fritters ⁽⁴⁴⁾, and polluted fomites ⁽⁴⁵⁾ are all normal transmission routes. Furthermore, unknown causes, like trauma, immunosuppressed condition, disruption of the natural epithelial wall, adventured gash result, abnormalities of adnexal structures, and other factors, increase the probability of ⁽⁴⁴⁾ and contaminated food sources ⁽⁴⁵⁾. trauma, immunosuppressed condition, disruption of the natural epithelium wall, adventured gash results, abnormalities of adnexal structures, etc., could cause the probability of 4) and contaminated food sources ⁽⁴⁵⁾ are common transmission routes. Moreover, unknown causes like trauma, immunosuppressed condition, disruption of the natural epithelium wall, adventured gash result, abnormalities of adnexal structures, and so on may cause compacted bacterial conjunctivitis ⁽⁴⁴⁾ Gram-negative gut bacteria, Haemophilus influenza, Streptococcus class, Moraxella catarrhalis, and Staphylococcus class are the most common causes of acute bacterial conjunctivitis. ⁽⁴⁶⁾ S. pneumonia or H. influenza may be the cause of minor illnesses in children. Non-native body sensation and rapid optical concealment are symptoms of acute bacterial conjunctivitis, which include mild conjunctival hyperaemia. (Figure 4) Various studies on bacterial conjunctivitis ^(47, 48) have found that itching and sticky eyelids may be present in about 90% of cases; these findings are followed by signs and symptoms that are less common, like purulent concealment and optical burning. H. influenza conjunctivitis may be associated with upper respiratory infections and acute otitis media. ⁽⁴⁶⁾

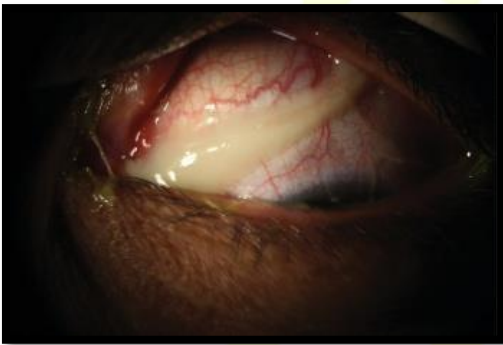


Figure 4: A person who has acute bacterial conjunctivitis and a thick, purulent discharge

6) Keratoconjunctivitis vernal (VKC)

It is believed that VKC represents the intricacy of younger boys with softer personalities. ^(49, 50) Even while VKC is more commonly diagnosed in children, it can affect adults as well. ⁽⁵¹⁾ This condition regularly exhibits an array of reactions of both IgE as well as non-IgE to general stimuli such wind, dirt, and sunshine. Consequently, assays for surface-visible allergens along with blood IgE antibody testing are often in the negative. ⁽⁵²⁾ The simultaneous function of IgE and T-adjuvant 2 in the it along with histological evidence support the pathogenesis of VKC. ⁽⁵³⁾ IL-17 and VKC have recently been linked, and the significance of the illness may be revealed by the antibody level in the blood. ^(54, 55) The high likelihood of antinuclear antibody (Corpus) positivity and blood records of autoimmune diseases in those with VKC suggests a strong correlation

between VKC and several autoimmune disorders, including atopy. Photophobia, flowing tears, severe itching, and conjunctival injections are the main clinical signs and symptoms of VKC ^(56, 57). Palpebral, limbal, and mixed types are the three clinical manifestations of VKC.

When the complication is alive, Horner-Trantas splotches are often seen at the superior limbal perimeters. A limbal papillary response and the limbus' sticky thickening distinguish the limbal type. ⁽⁵⁸⁾ The palpebral VKC is distinguished by massive papillae with a cobblestone appearance. In the mixed type, limbal and palpebral VKC characteristics are present at the same time.

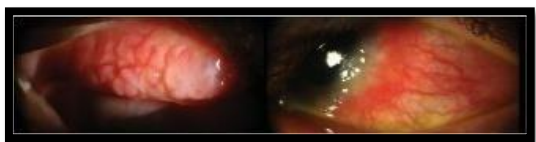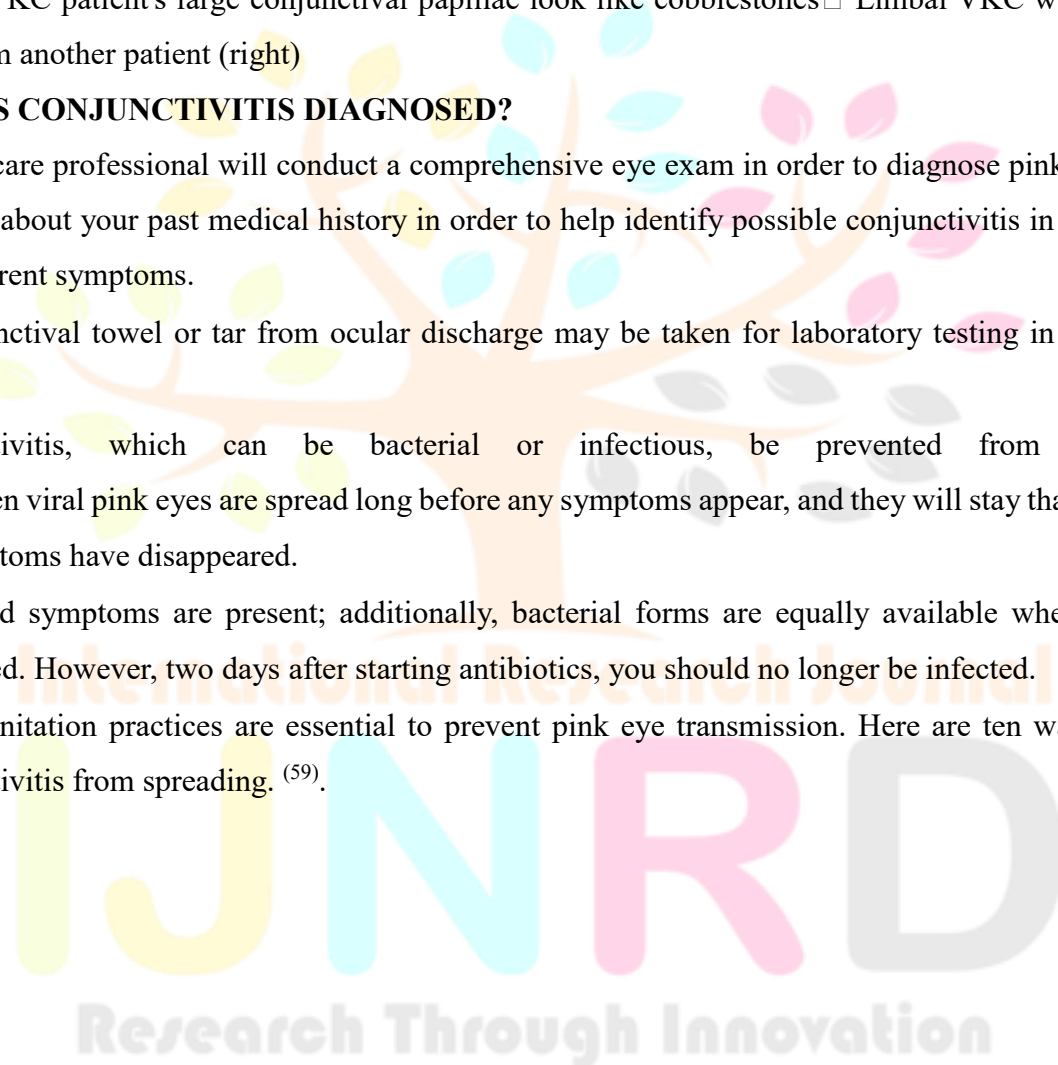


Figure 5: Left: VKC patient's large conjunctival papillae look like cobblestones □ Limbal VKC with Horner-Trantas dots from another patient (right)

➤ HOW IS CONJUNCTIVITIS DIAGNOSED?

An eye care professional will conduct a comprehensive eye exam in order to diagnose pink eye. They will ask about your past medical history in order to help identify possible conjunctivitis in addition to your current symptoms.

- A conjunctival towel or tar from ocular discharge may be taken for laboratory testing in rare cases.
- conjunctivitis, which can be bacterial or infectious, be prevented from spreading
The seven viral pink eyes are spread long before any symptoms appear, and they will stay that way until all symptoms have disappeared.
- signs and symptoms are present; additionally, bacterial forms are equally available when they are undressed. However, two days after starting antibiotics, you should no longer be infected.
- Basic sanitation practices are essential to prevent pink eye transmission. Here are ten ways to stop conjunctivitis from spreading. ⁽⁵⁹⁾.



➤ Prevention Tips:

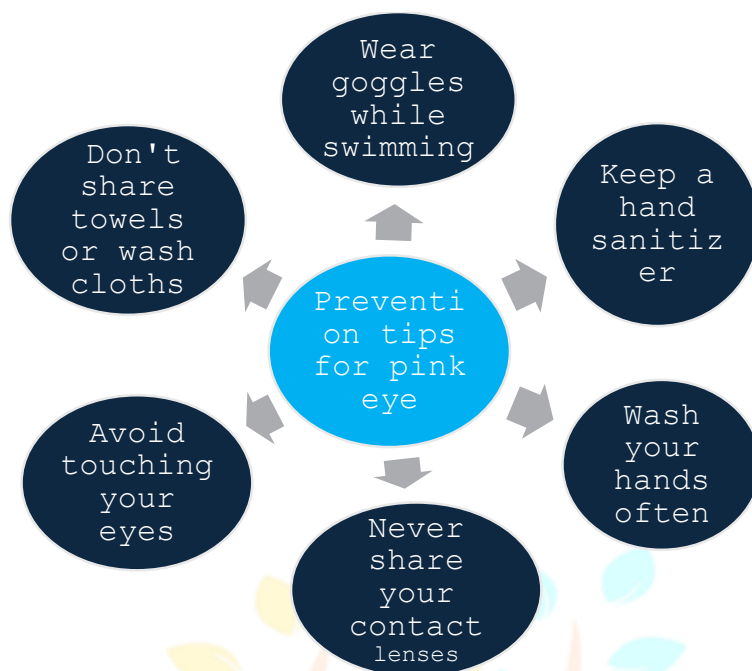

Fig 6 Prevention Tips

➤ DOSAGE FORMS OF TOPICAL OPHTHALMIC DRUGS:

1) Liquid dosage Forms :

- **Eye Drops:** Eye drops can be purchased as water or oil painting results, mixtures, or dormancies of one or more active ingredients; if preserved in multiuse packaging, the eye drops may contain preservatives. These are isotonic and sterile forms. The ideal pH for eye drops is approximately 7.4, which is the same as gash fluid. The stability of the active ingredient and the towel's resistance to the medication should be considered when determining if to cushion the medication in this way ^(60, 61). However, if the pH value falls outside of the 4–8 range that the eye permits, the case may experience discomfort and vexation.

- **Ophthalmic Solutions:** Waterless results are employed, and sterile results are obtained. Ophthalmic outcomes are waterless, sterile, and employed for a variety of purposes, including irrigating eyes and sanctifying them. They might include excipients that control the drug's density, pH, and bibulous pressure, among other things. If they are kept in multiuse packaging, they could additionally contain preservatives ⁽⁶⁰⁾.

2) Solid dosage Forms :

- **Contact lenses coated in medication.** This type of medication is released after being applied to the eyeball for an extended period of time and has the ability to absorb water-soluble substances on its face ^(63, 64)

- **Optical Inserts:** These are circumfluous or solid lozenges that do not have the drawbacks of conventional ophthalmic pharmaceutical forms ^(64, 65). They are less vulnerable to defensive systems. Similar to emigration through the nasolacrimal conduit, they exhibit a longer duration of stay in the conjunctival sac and are more secure than traditional dosage forms. Aside from proper dosing, their unavoidable benefits over conventional forms include the ability to reduce chemical release at a steady speed and the ability to minimize systemic

immersion. Additionally, utilizing them permits a decrease in the frequency of medication operations, bad effects, and situations involving blurred vision ^(66, 65).

- **Minitablets:** Minitablets are solid, biodegradable medication forms that are transported into gels after being inserted into the conjunctival sac. This prolongs the contact time between the active component and the ocular face, increasing the Active Components bioavailability.⁽⁶⁷⁾ Minitablets have the following benefits: they are simple to use with the conjunctival sac, resistant to defences mechanisms similar as tearing or exodus through the as nasolacrimal conduit, have a mucoadhesive polymer that prolongs contact with the cornea, and release the active component gradually from the expression in the Because of the bulk of the external carrier layers in the expression at the surgery site.^(68,69)

- **Collagen Shield:** Porcine sclera is used to create collagen shields since the collagen in these tissues resembles that of human corneas. Before being exposed to the eye, the securities are drenched and kept in a dry state. When typical collagen securities are put by an ophthalmologist, they don't fit the patient's eyeball well and cause some discomfort because they snoop around in the eyes. Additionally, they could unintentionally come out of the eye right after the preamble.

⁽⁶⁴⁾ The so-called collasomes, which are tiny fragments of collagen (1 mm x 2 mm × 0.1 mm) suspended from a 1 methylcellulose medium, are more modern collagen lozenge forms. Collasomes exhibit all of the benefits of collagen securities without any drawbacks. ^(64,70)

3) Semisolid dosage forms :

- **Eye Ointments:** Ointments are superfluous lozenges applied externally that typically consist of a solid or superfluous hydrocarbon base with a melting or softening point that is not much advanced than the temperature of a person's body. The ointment breaks down into tiny drops when it is applied to the eye, and these droplets remain in the conjunctival sac longer, increasing the medicine's bioavailability. Eye ointments have distinct drawbacks; while generally safe and well-tolerated, they can induce blurred vision and occasionally prickly sensations, which makes them a significant source of darkness. ⁽⁶⁶⁾

- **Hydrogels as versatile drug delivery methods for the management of ophthalmic complications:**

To prolong the corrective immersion of ocular drugs within the front and/or rearward sections, several optical pharmaceutical delivery methods and mechanisms have been devised. Hydrogel seem to contribute to the advancement of medicine among them. As three-dimensional network structures, hydrogels can transport medications to various sites of action through a variety of delivery methods (Fig. 1), including topical application, intracameral injection, and intravitreal injection ^(71,72). Due to the constant laceration product (0.5–2.2 μL/min) and laceration development ⁽⁷³⁾, the medication's contact time on the optical outer serviettes is just 1–2 minutes. Hydrogels are useful for preventing bleeding and blinking, which prolongs the time that medication is present on the outside and allows more medication to function locally on mucosal surfaces.

Hydrogels have the ability to prolong the duration of medication habitation on the optical face and to maintain drug release in intraocular serviettes, much like waterless humour and vitreous depression ^(74, 75). Patient compliance would decline with more frequent administration. Hydrogels have the ability to effectively achieve original attention while providing a continuous release of medications in waterless humour. Furthermore, several optical medications, particularly biologics, have a brief half-life (less than one week) and/or poor

stability in the vitreous humour. These biologics can be encapsulated in hydrogels to increase their potency and prolong the release of medication. Certain optical problems (such as glaucoma and retinal conditions) require more than one cure to achieve optimal therapeutic efficacy. Combination therapy, which involves administering two or more corrective medicines at the same time, has emerged as a crucial tactic to improve healthcare outcomes with complementary products. Hydrogels have the potential to combine many medications on a single platform, resulting in enhanced therapeutic efficacy. ⁽⁷⁶⁾

Hydrogels are generally an efficient method of delivery for optical medicine because they can: 1) prolong the medicine hearthstone time during the administration point; 2) release medicine gradually at the target point; and 3) co-deliver multiple medicines. These findings are consistent with each other. The next sections will provide a detailed introduction to polychromatic corresponding hydrogels used in optical medicine delivery, emphasising their many captivating applications. The next sections will provide a detailed introduction to representative hydrogels utilised in ocular medication administration, highlighted by a few visually appealing examples.

Applications of hydrogel

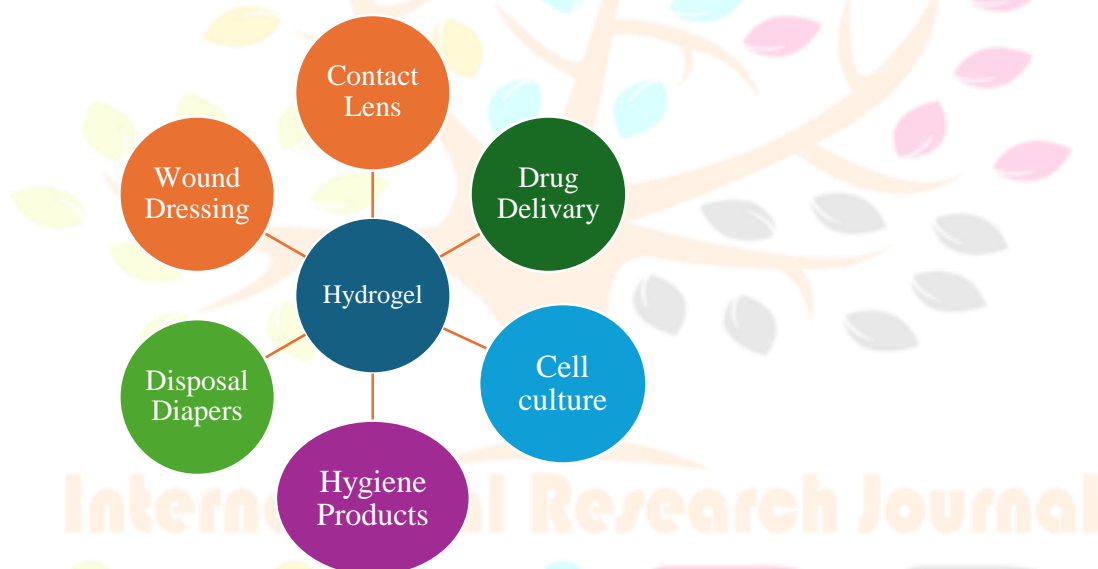

Figure 7 :Applications of hydrogel

➤ Purpose of hydrogel for ocular drug delivery:

One of the causes of blindness is cataract, which is brought on by a progressive loss of the lens's transparency or by a change in the protein of the lens.⁹⁷ During cataract surgery, the lens is typically replaced, which makes the intraocular lens extremely crucial. Owing to advancements in cataract surgery, a smaller incision is needed for the foldable intraocular lens during the procedure. The use of hydrogels as intraocular lenses has numerous benefits. As an illustration, they are autoclavable, foldable, and contain a lot of water. The natural lens is a type of hydrogel, and they have long been employed as intraocular lenses. One of the causes of blindness is cataract, which is brought on by a progressive loss of the lens's transparency or by a change in the protein of the lens. During cataract surgery, the lens is typically replaced, which makes the intraocular lens extremely crucial. Owing to advancements in cataract surgery, a smaller incision is needed for the foldable intraocular lens during the procedure. The use of hydrogels as intraocular lenses has numerous benefits. As an

illustration, they are autoclavable, foldable, and contain a lot of water. The natural lens is a type of hydrogel, and they have long been employed as intraocular lenses.

➤ Advantages of Hydrogels

- Due to their high water content, hydrogels have a degree of flexibility comparable to natural tissue.
- Hydrogel beads capture microbial cells because they are not toxic.

Environmentally perceptive hydrogels can describe changes in pH, temperature, or metabolite concentration and accordingly release their cargo.

- Timely release of growth factors and other nutrients to ensure proper tissue growth.
- Hydrogels possess excellent transport properties.
- Biocompatible hydrogels.
- Injectable hydrogels are available.
- Hydrogels are biocompatible and easily modifiable.
- **Disadvantages of Hydrogels**
- Hydrogels bring a precious.
- Bees move to feel hydrogels.
- The surgical risk associated with devide implantation and retrieval.
- Hydrogels don't stick; a secondary dressing may be needed to keep them safe.
- When used as contact lenses, hydrogels cause lens accumulation, hypoxia, dehydration, and red eye reactions.
- They are non-adherent and may require secondary clothing.
- **In-situ gelling hydrogels:**

These hydrogels are liquids that go through a phase change in the ocular membranes to produce a viscoelastic gel. This process extends the time that pharmaceuticals are retained in the ocular tissues and/or sustains their release, which increases the drug's ocular bioavailability. Physiological cues like pH, ions, and temperature can cause gelation⁽⁷⁷⁾. In this part, we will review some in-situ gelling hydrogels used in ocular medication administration.

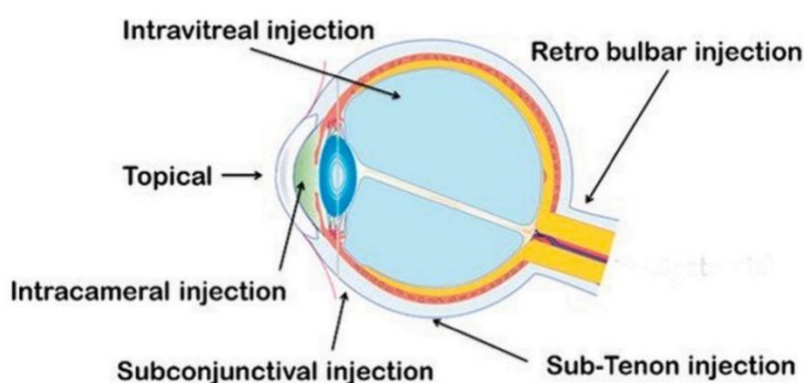


Fig. 8. Schematic illustration of the ocular administration routes of hydrogels.

➤ CONCLUSION:

Hydrogels have proven to be able to extend the time that an active ingredient is present, allowing for faster prolixity across the layers of the eye. This suggests a way to counteract the shortcomings of traditional pharmaceutical forms while also increasing the bioavailability of ocular formulations applied topically. Clinical investigations and the encouraging content of mistreated products attest to the efficaciousness of hydrogel-based ophthalmic medicine delivery methods in treating visual diseases. More focus must be placed on using

hydrogels to transport complex biomacromolecules in order to cure retinal diseases and improve their clinical outcomes.

➤ REFERENCE

- 1) S. Deepthi Jobinase, *Review on Novel Hydrogel -based Ocular Drug Delivery system. For the Treatment Conjunctivitis* .<https://doi.org/10.1007/s10792018-0955-6>
- 2) Amira. Azari, Amir Arabi, *Conjunctivitis: A Systematic Review* DOI: [10.18502/jovr.v15i3.7456](https://doi.org/10.18502/jovr.v15i3.7456)
- 3) Prashant S.. Malpure, Shital. S. Patil : *A Review on Hydrogel*. DOI: [10.46624/ajptr.2018.v8.i3.005](https://doi.org/10.46624/ajptr.2018.v8.i3.005)
- 4) Insan Sunan Kurniawansyah, Iyan Sopyan, *Formulation and Evaluation of Chloramphenicol Hydrogel Ophthalmic Preparation* DOI: [10.5530/1jYp.2018.25.14](https://doi.org/10.5530/1jYp.2018.25.14)
- 5) Andrew F Smith ,Curtis Waycaster, *Estimate of the direct and indirect annual cost of bacterial conjunctivitis in the United States*. DOI: [10.1186/1471-2415-9-13](https://doi.org/10.1186/1471-2415-9-13)
- 6) Acurti S. Baware D .K. Vir. *Eye Conjunctivitis*. DOI:[10.5281/zenodo.10441975](https://doi.org/10.5281/zenodo.10441975)
- 7) M A Tipple, M O Beem, E M Saxon. *Clinical characteristics of the afebrile pneumonia associated with Chlamydia trachomatis infection in infants less than 6 months of age*. *Pediatrics* 1979; 63:192– 197
- 8) De Toledo A .R, Chandler J. W, *Conjunctivitis of the New-Born*. 6:807– 813.
- 9) Bodor F. F. *Conjunctivitis-otitis syndrome*. *Pediatrics* 1982; 69:695–698.
- 10) Kowalski R .P, Karenchak L. *Infectious disease: changing antibiotic susceptibility*. 2003; 16:1–9.
- 11) Galor A, Jeng B H. *Red Eye for the Internist: When to treat, when to Refer* DOI: [10.3949/ccjm.75.2.137](https://doi.org/10.3949/ccjm.75.2.137)
- 12) Dr. Vanuli Bajpai, Consultant - Ophthalmology, HCMCT Manipal Hospitals, Dwarka, *Review on Eye Flu (Conjunctivitis): Symptoms, Prevention And Home Care*.
- 13) Moura, F. E, Ribeiro, D.C. Gurgel,. *Acute Haemorrhagic Conjunctivitis Outbreak in the city of Fortaleza, Northea Brazil* ,DOI: [10.1136/bjo.2006.098822](https://doi.org/10.1136/bjo.2006.098822)
- 14) Wright, P. W., Strauss, G. H. *Acute hemorrhagic conjunctivitis*. 45, 173-178.
- 15) Cabrerizo, M ,Echevarria, J. E. Otero, A. *Molecular Characterization of a Coxsackievirus A24 variant that caused an outbreak of Acute Haemorrhagic conjunctivitis in Spain 2004* DOI: [10.1016/j.jcv.2008.07.017](https://doi.org/10.1016/j.jcv.2008.07.017)
- 16) Wu, D., Ke, C. W., Mo, Y. L., Sun, L. M., Li, H., Chen, Q. X., Zou, L. R., Fang, L., Huang, P.and Zhen, H. Y. (2008). *Multiple outbreaks of acute hemorrhagic conjunctivitis due to a variant of Coxsackievirus A24: Guangdong*. *J Med Virol*, 80, 1762-1768.
- 17) Goh, K. T., Ooi, P. L., Miyamura, K., Ogino, T. and Yamazaki, S. (1990). *Acute haemorrhagic conjunctivitis: seroepidemiology of coxsackievirus A24 variant and enterovirus 70 in Singapore*. *J Med Virol*, 31, 245-247.
- 18) Oh, M., Park, S., Choi, Y., Kim, H., Lee, K., Park, W., Yoo, Y., Kim, E. and Choe, K. (2003). *Acute hemorrhagic conjunctivitis caused by coxsackievirus A24 variant*. *Emerg Infect Dis*, 9, 1010-1012.
- 19) Bielory, L. (2008). *Ocular allergy overview*. *Immunol Allergy Clin North Am*, 29, 1-23.
- 20) Pelikan, Z. (2009). *Seasonal and perennial allergic conjunctivitis:the possible role of nasal allergy*. *Clin Exp Ophthalmol*, 37, 448-457.
- 21) Pelikan, Z. *The possible involvement of Nasal Allergy in Allergic Keratoconjunctivitis*. *Eye*, DOI: [10.1038/eye.2008.341](https://doi.org/10.1038/eye.2008.341)
- 22) Pelikan, Z. *Seasonal and Perennial Allergic Conjunctivitis: the possible role of Nasal Allergy*. DOI: [10.1111/j.1442-9071.2009.02079](https://doi.org/10.1111/j.1442-9071.2009.02079).

- 23) Bacon, A. S, Ahluwalia, P, Irani, A. M, Schwartz, L. B., Holgate, *Tear and Conjunctival changes during the Allergen-induced early- and late-phase responses*. DOI: 10.1067/mai.2000.110930
- 24) Stenson S, Newman R, Fedukowicz H. *Laboratory studies in Acute Conjunctivitis*. DOI: 10.1001/archophth.1982.01030040253009
- 25) Fitch CP, Rapoza PA, Owens S, Murillo-Lopez F, Johnson A, Quinn TC, et al. *Epidemiology and diagnosis of acute conjunctivitis at an inner-city hospital*. *Ophthalmology* 1989;96:1215–1220.
- 26) Newman H, Gooding C. *Viral ocular manifestations: a broad overview*. *Rev Med Virol* 2013;23:281–294.
- 27) O'Brien TP, Jeng BH, McDonald M, Raizman MB. *Acute conjunctivitis: truth and misconceptions*. *Curr Med Res Opin* 2009;25:1953–1961.
- 28) Singh G, Zhou X, Lee JY, Yousuf MA, Ramke M, Ismail AM, et al. *Recombination of the epsilon determinant and cornealtropism: human adenovirus species D types 15, 29,56, and 69*. *Virology* 2015;485:452–459.
- 29) Kuo IC. *Adenoviral keratoconjunctivitis: diagnosis, management, and prevention*. *Curr Ophthalmol Rep* 2019;7:118–127.
- 30) Li J, Lu X, Sun Y, Lin C, Li F, Yang Y, et al. *A swimming pool-associated outbreak of pharyngoconjunctival fever caused by human adenovirus type 4 in Beijing, China*. *Int J Infect Dis* 2018;75:89–91.
- 31) Sinclair RG, Jones EL, Gerba CP. *Viruses in recreational water-borne disease outbreaks: a review*. *J Appl Microbiol* 2009;107:1769–1780.
- 32) Harley D, Harrower B, Lyon M, Dick A. *A primary school outbreak of pharyngoconjunctival fever caused by adenovirus type 3*. *Comm Dis Intell* 2001;25:9–12.
- 33) Chintakuntlawar AV, Chodosh J. *Cellular and tissue architecture of conjunctival membranes in epidemic keratoconjunctivitis*. *Ocul Immunol Inflamm* 2010;18:341–345
- 34) Cronau H, Kankanala RR, Mauger T. *Diagnosis and management of red eye in primary care*. *Am Fam Phys* 2010;81:137–144.
- 35) Papa V, Aragona P, Scuderi AC, Blanco AR, Zola P, Alessandro Di B, et al. *Treatment of acute bacterial conjunctivitis with topical netilmicin*. *Cornea* 2002;21:43–47.
- 36) Puri LR, Shrestha GB, Shah DN, Chaudhary M, Thakur A. *Ocular manifestations in herpes zoster ophthalmicus*. *Nepal J Ophthalmol* 2011;3:165–171.
- 37) Sy A, McLeod SD, Cohen EJ, Margolis TP, Mannis MJ, Lietman TM, et al. *Practice patterns and opinions in the management of recurrent or chronic herpes zoster ophthalmicus*. *Cornea* 2012;31:786–790.
- 38) Lim KH, Yin-Murphy M. *Epidemic conjunctivitis in Singapore in 1970 and 1971*. *Singapore Med J* 1973;14:86–89.
- 39) Zhang L, Zhao N, Huang X, Jin X, Geng X, Chan T-C, et al. *Molecular epidemiology of acute hemorrhagic conjunctivitis caused by coxsackievirus A type 24 variant in China, 2004-2014*. *Sci Rep* 2017;7:45202.
- 40) Langford MP, Anders EA, Burch MA. *Acute hemorrhagic conjunctivitis: anti-coxsackievirus A24 variant secretory immunoglobulin A in acute and convalescent tear*. *Clin Ophthalmol* 2015;9:1665–1673.
- 41) Epling J. *Bacterial conjunctivitis*. *BMJ Clin Evid* 2012;2012:0704.
- 42) Shields T, Sloane PD. *A comparison of eye problems in primary care and ophthalmology practices*. *Fam Med* 1991;23:544–546.
- 43) Gallenga PE, Lobefalo L, Colangelo L, Della Loggia G, Orzalesi N, Velati P, et al. *Topical lomefloxacin 0.3% twice daily versus tobramycin 0.3% in acute bacterial conjunctivitis: a multicenter double-blind phase III study*. *Ophthalmologica* 1999;213:250–257.

- 44) Varu DM, Rhee MK, Akpek EK, Amescua G, Farid M, Garcia-Ferrer FJ, et al. *Conjunctivitis preferred practice pattern*®. *Ophthalmology* 2019;126:P94–P169.
- 45) Karpecki P, Depaolis M, Hunter JA, White EM, Rigel L, Brunner LS, et al. *Besifloxacin ophthalmic suspension 0.6% in patients with bacterial conjunctivitis: A multicenter, prospective, randomized, double-masked, vehicle-controlled, 5-day efficacy and safety study*. *Clin Ther* 2009;31:514–526.
- 46) Hovding G. *Acute bacterial conjunctivitis*. *Acta Ophthalmol* 2008;86:5–17.
- 47) Horven I. *Acute conjunctivitis. A comparison of fusidic acid viscous eye drops and chloramphenicol*. *Acta Ophthalmol* 1993;71:165–168.
- 48) Wall AR, Sinclair N, Adenis JP. *Comparison of fucithalamic (fusidic acid viscous eyedrops 1%) and noroxin (norfloxacin ophthalmic solution 0.3%) in the treatment of acute bacterial conjunctivitis*. *J Drug Assess* 1998;1:549–558.
- 49) Sofi RA, Mufti A. *Vernal keratoconjunctivitis in Kashmir: a temperate zone*. *Int Ophthalmol* 2016;36:875–879.
- 50) Katelaris CH. *Ocular allergy in the Asia Pacific region*. *Asia Pac Allergy* 2011;1:108–114.
- 51) De Smedt S, Wildner G, Kestelyn P. *Vernal keratoconjunctivitis: an update*. *Br J Ophthalmol* 2013;97:9–14.
- 52) Jun J, Bielory L, Raizman MB. *Vernal conjunctivitis*. *Immunol Allergy Clin North Am* 2008;28:59–82, vi.
- 53) Zicari AM, Capata G, Nebbioso M, De Castro G, Midulla F, Leonardi L, et al. *Vernal keratoconjunctivitis: an update focused on clinical grading system*. *Ital J Pediatr* 2019;45:64.
- 54) Zicari AM, Nebbioso M, Zicari A, Mari E, Celani C, Occasi F, et al. *Serum levels of IL-17 in patients with vernal keratoconjunctivitis: a preliminary report*. *Eur Rev Med Pharmacol Sci* 2013;17:1242–1244.
- 55) Validad MH, Khazaei HA, Pishjoo M, Safdari Z. *The study of Interleukin-17 level in vernal keratoconjunctivitis disease and its relationship between symptom and sign severity*. *Sem Ophthalmol* 2017;32:721–724.
- 56) Occasi F, Zicari AM, Petrarca L, Nebbioso M, Salvatori G, Duse M. *Vernal keratoconjunctivitis and immune-mediated diseases: one unique way to symptom control?* *Pediatr Allergy Immunol* 2015;26:289–291.
- 57) Zicari AM, Nebbioso M, Lollobrigida V, Bardanzellu F, Celani C, Occasi F, et al. *Vernal keratoconjunctivitis: atopy and autoimmunity*. *Eur Rev Med Pharmacol Sci* 2013;17:1419–1423.
- 58) Rathi VM, Murthy SI. *Allergic conjunctivitis*. *Commun Eye Health* 2017;30:S7–S10.
- 59) By Amber MC Manes. *Review on what is pink eye*.
- 60) Polish Pharmacopoeia, vol. 8, part 1, *The Office for Registration of Medicinal Products, Medical Devices and Biocidal Products, Warsaw, Poland, 2008*.
- 61) “The International Pharmacopoeia,” 4th Edition, 2013, <http://apps.who.int/phint/en/p/about>.
- 62) Jitendra, P. K. Sharma, A. Banik, and S. Dixit, “A new trend: ocular drug delivery system,” *An International Journal of Pharmaceutical Sciences*, vol. 2, no. 3, pp. 1–25, 2011.
- 63) A. Rajasekaran, K. S. G. A. Kumaran, J. P. Preetha, and K. Karthika, “A comparative review on conventional and advanced ocular drug delivery formulations,” *International Journal of PharmTech Research*, vol. 2, no. 1, pp. 668–674, 2010.
- 64) P. Tangri and S. Khurana, “Basics of ocular drug delivery systems,” *International Journal of Research in Pharmaceutical and Biomedical Sciences*, vol. 2, no. 4, pp. 1541–1552, 2011.

- 65) M. H. Aburahma and A. A. Mahmoud, "Biodegradable ocular inserts for sustained delivery of brimonidine tartarate: preparation and in vitro/in vivo evaluation," AAPS PharmSciTech, vol. 12, no. 4, pp. 1335–1347, 2011.
- 66) K. S. Rathore and R. K. Nema, "An insight into ophthalmic drug delivery system," International Journal of Pharmaceutical Sciences and Drug Research, vol. 1, no. 1, pp. 1–5, 2009.
- 67) W. Weyenberg, A. Vermeire, J. Vandervoort, J. P. Remon, and A. Ludwig, "Effects of roller compaction settings on the preparation of bioadhesive granules and ocular minitablets," European Journal of Pharmaceutics and Biopharmaceutics, vol. 59, no. 3, pp. 527–536, 2005.
- 68) R. M. Moosa, Y. E. Choonara, L. C. du Toit et al., "A review of topically administered mini-tablets for drug delivery to the anterior segment of the eye," Journal of Pharmacy and Pharmacology, 2013.
- 69) H. Abd El-Gawad, O. A. Soliman, S. A. Barker, and G. N.S. Girgis, "Formulation and evaluation of gel forming ocular minitablets containing piroxicam," British Journal of Pharmaceutical Research, vol. 2, no. 3, pp. 141–167, 2012.
- 70) D. Karthikeyan, M. Bhowmick, V. P. Pandey et al., "The concept of ocular inserts as drug delivery systems: an overview," Asian Journal of Pharmaceutics, vol. 2, no. 4, pp. 192–200, 2008.
- 71) D. Chang, K. Park, A. Famili, *Drug Discover. Today* 24 (2019) 1470–1482.
- 72) M. Dubald, S. Bourgeois, V. Andrieu, H. Fessi, *Pharmaceutics* 10 (2018).
- 73) E. Sanchez-López, M. Espina, S. Doktorovova, E.B. Souto, M.L. García, *Eur. J. Pharm. Biopharm.* 110 (2017) 70–75.
- 74) B.C. Ilochonwu, A. Urtti, W.E. Hennink, T. Vermonden, *J. Control. Release* 326 (2020) 419–441.
- 75) Q. Han, Y. Wang, X. Li, R. Peng, A. Li, Z. Qian, L. Yu, *J. Mater. Sci. Mater. Med.* 26 (2015) 225.
- 76) J. Xu, Y. Ge, R. Bu, A. Zhang, S. Feng, J. Wang, J. Gou, T. Yin, H. He, Y. Zhang, X. Tang, *J. Control. Release* 305 (2019) 18–28.
- 77) Y. Wu, Y. Liu, X. Li, D. Kebebe, B. Zhang, J. Ren, J. Lu, J. Li, S. Du, Z. Liu, *Asian J. Pharm. Sci.* 14 (2019) 1–15.

