



LOBULAR CAPILLARY HEMANGIOMA OF STOMACH: A RARE CASE REPORT

Dr G K Parvathi Devi, Dr Rebekah M, Sriharsha. H. V

Professor, intern

Sri Siddartha Medical College, Tumkur

Background:

Lobular capillary hemangioma also known as pyogenic granuloma is a benign tumor which is commonly seen in sites like skin and mucosal surfaces of oral cavity. But can also be seen in unusual sites like gastrointestinal tract, nose, larynx, eye and urogenital tract. We are presenting one such case.

Case details:

A 70-year-old male presented with an history of heart burns and pain in epigastric region. Endoscopy showed a pedunculated lesion in the body of the stomach. Endoscopic polypectomy was done and specimen was sent for HPE which showed grossly a reddish, ovoid polypoidal mass measuring 1x1x0.5cm with reddish areas on cut surface. Microscopy shows polyp with many lobules of tiny capillaries in lamina propria admixed with inflammatory infiltrates along with benign appearing gastric glands. No bacterial colonies near neutrophils noted ruling out bacillary angiomatosis. No spindle cells or atypia seen ruling out Kaposi sarcoma. No hyperplasia of glands seen.

And diagnosis of Lobular capillary hemangioma was made.

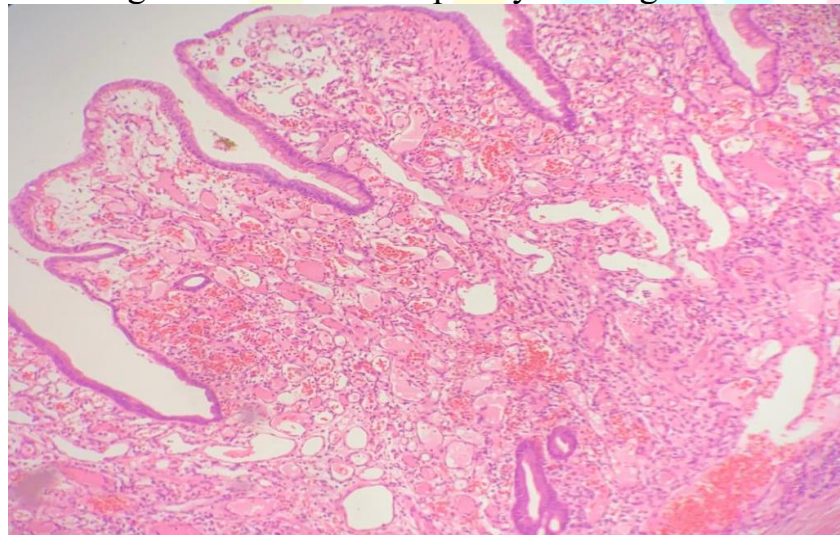


Fig 1 ; Micro photograph shows endoscopic appearance of gastric polypoid nodule at x10

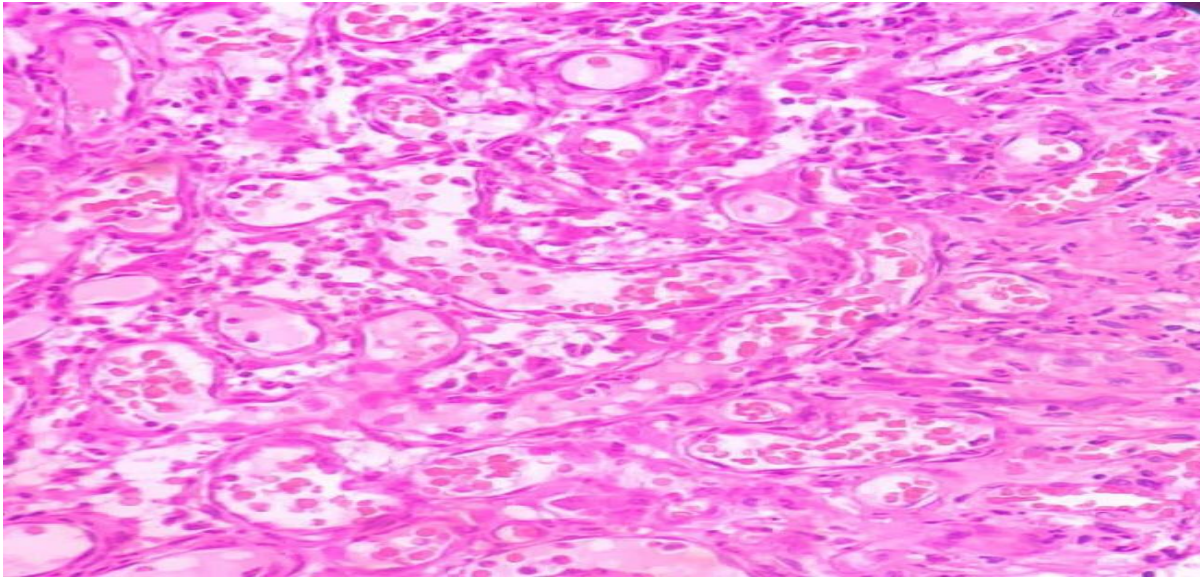


Fig 2; Micro photograph shows a capillary hemangioma is present and arranged in a lobular pattern and filled with clusters of small capillary vessels ×40

Discussion:

Lobular capillary hemangioma or Pyogenic granuloma was first reported in 1920 by Hatzell. Approximately 65 cases have been reported till date. It is a benign vascular tumor commonly occurring in skin followed by oral mucosa. Due to characteristic feature of hypervascularization and location easy bleeding is common. Pathogenesis includes predisposing factors like chronic irritation, liver cirrhosis, few drugs like OCP and retinoids and hormonal changes. It can also be a cause for gastrointestinal bleeding. Immunohistochemistry CD31 or CD34 can be useful to distinguish between pyogenic granuloma and inflammatory polyp.

Conclusion:

Gastric lobular capillary hemangioma is a rare benign proliferative tumor. Awareness of this rare entity is important for timely diagnosis and treatment. Since it's rare we are presenting this case.