IJNRD.ORG ISSN : 2456-4184
INTERNATIONAL JOURNAL OF NOVEL RESEARCH AND DEVELOPMENT (IJNRD) | IJNRD.ORG
An International Open Access, Peer-reviewed, Refereed Journal

Review on: intravitreal injections advancement

Vaishnavi B. Salokhe*, Aarti A. Varne, Shobha H. Pukale, Pooja A. Chimane, Snehal S. Jarag

Department of Pharmaceutical Chemistry

Anandi Pharmacy College Kalambe Tarf kale, pin 416205, Maharashtra India.

Abstract: The medical treatment of retina diseases has completely changed after introducing intravitreal therapy with anti-VEGF agents. This advancement could be considered the most remarkable breakthrough in ophthalmology of the new century. This sight-saving therapy is the gold standard treatment for most common macular diseases, such as application age-related macular degeneration (AMD), diabetic macular edema (DME), and macular edema secondary to retinal vein occlusion (RVO), Uveitic Macular Edema steroid and macular edema. The equipment is most important and intravitreal injection is the most frequently performed eye procedure in the world and is an essential component in the management of sight-threatening retinal diseases and conditions. Given the seriousness and range of diseases treated and the procedure's risks, retina specialists must weigh the pros and cons of each treatment. Complexities guiding injection treatment are multifaceted and involve patient-history review, careful examination, diagnostic testing selection and interpretation, and customized medical decision-making. This article aimed to review the role of intravitreal injections of medications in the treatment, and techniques or therapeutics of the 2 common macular diseases, ME caused by diabetes mellitus, retinal vascular diseases, uveitis, and AMD.

Keywords: Intravitreal injection, age-related macular, diabetic macular edema, macular edema secondary to retinal vein occlusion, ophthalmology.

INTRODUCTION: Intravitreal injection is a common procedure performed by ophthalmologists. It is a quick and targeted treatment for several ophthalmic conditions. Despite this, the potential to cause serious complications and patient discomfort cannot be ignored. Intravitreal injections are currently an integral part of the practice of ophthalmology and are a widely accepted method for intraocular drug delivery. Until only 15 years ago, this procedure was performed much less frequently and was reserved for delivering antibiotics in cases of endophthalmitis patients with macular edema. or steroids in Following the introduction of anti-vascular Endothelial Growth Factor (VEGF) agents, the use of intravitreal injections increased exponentially, and they quickly became the most commonly performed procedure in ophthalmology. The first anti-VEGF agent to be approved by the FDA was pegaptanib sodium (Macugen, Pfizer), which was effective in improving visual acuity in patients with neovascular age-related macular degeneration (AMD), but as it only inhibited one isoform of VEGF-A it is no longer used. Soon after ranibizumab (Lucentis, Genentech) was

developed, and demonstrated excellent results in treating neovascular AMD in the seminal MARINA and ANCHOR studies. Other anti-VEGF agents in common use are bevacizumab (Avastin, Genentech), which is extensively used off-label for economic reasons, and aflibercept (Eylea, Regeneron). The efficacy and excellent safety profile of anti-VEGF agents administered by intravitreal injections have been demonstrated in numerous large-scale randomized controlled trials, for a wide variety of retinal diseases, including neovascular AMD, diabetic macular edema (DME), and retinal vein occlusions (RVOs). The prevalence of diabetes mellitus (DM) has progressively increased recently worldwide and 430 million people around the globe are predicted to have DM by the year 2030. In the United States, an estimated 29% of adult patients with DM have diabetic retinopathy (DR) and 3% have diabetic macular edema (DME), with DM being the leading cause of blindness in people between the ages of 20 and 74 years. DME is an increase in the thickness of the central macular region of the retina due to fluid accumulation that is frequently associated with loss of vision. Commonest cause of vision loss in diabetics and affects an estimated 21 million people worldwide. Treatment of macular edema due to various retinal conditions, including DME, currently depends on the repeated intravitreal injection of anti-vascular endothelial growth factor (anti-VEGF) agents. This may be because VEGF is central to the pathogenesis of many of these retinal conditions including DR and DME. VEGF-A is a member of the VEGF family that is the most implicated in the pathogenesis of various retinal diseases due to its pro-angiogenic and Vaso-permeability effects that result in disruption of the blood-retinal barriers, it has five different isoforms, and most of the currently available anti-VEGF agents block all these isoforms. VEGF also has several physiologic functions including regulation of normal vasculogenesis and angiogenesis, acting as a survival factor for retinal vessels during their development, maintenance of the choriocapillaris and consequently the photoreceptors, and possessing a neuroprotective role that leads to the reduction of neuronal apoptosis. This raises concerns regarding the long-term suppression of intraocular VEGF levels using intravitreally injected ti-VEGF agents that are frequently needed for the long-term treatment of retinal diseases. Intravitreal injection is the most common eye procedure worldwide1 and is increasing in use by 6% annually in the United States.2 Intravitreal injections have revolutionized retinal disease management and enabled dramatically improved prognosis to patients with potentially blinding retinal disease. Despite being common, intravitreal injection therapy is rarely "standard," given the complexity of decision-making required for patients' treatment. Intravitreal injection treatment is guided by individual patient's factors, and therapy is tailored to achieve the best outcome for each patient. Since the approval of the first ant-vascular endothelial growth factor (anti-VEGF) injection therapy in 2005, ophthalmologists have come to learn through experience that real-world patients undergoing treatment of retinal disease are quite different from the patients who met the inclusion and exclusion criteria of the registration studies that led to commercial availability. Owing to the restrictive criteria of clinical trials, most patients are not candidates for trial inclusion. There are numerous conditions for which intravitreal injections are not Food and Drug Administration (FDA) approved yet studies have demonstrated benefits (eg, ocular histoplasmosis, polypoidal choroidal vasculopathy, retinal arterial microaneurysm, cystoid macular edema [ME]). Furthermore, comorbid eye disease, systemic disease, or fellow eye disease may affect or add myriad complexities to a patient's disease management. A variety of drugs are delivered by intravitreal injection, some FDA-approved and some off-label. Because of unique circumstances, most patients are not on a fixed

treatment schedule and require examination of the eye(s) at customized intervals that deviate from the FDA label, including the "treat and extend" and "as-needed" treatment paradigms. Additionally, the number of FDA-approved.

(1) APPLICATION FOR INTRAVITREAL INJECTION ADVANCEMENT:

1.1 Age-related macular degeneration:

Age-related macular degeneration (AMD) is a leading cause of vision loss in the elderly. The current standard treatment for AMD involves frequent intravitreal administrations of therapeutic agents. While effective, this approach presents challenges, including patient discomfort, inconvenience, and the risk of adverse complications. Nanoparticle-based intravitreal drug delivery platforms offer a promising solution to overcome these limitations. These platforms are engineered to target the retina specifically and control drug release, which enhances drug retention, improves drug concentration and bioavailability at the retinal site and reduces the frequency of injections. This review aims to uncover the design principles guiding the development of highly effective nanoparticle-based intravitreal drug delivery platforms for AMD treatment. By gaining a deeper understanding of the physiology of ocular barriers and the physicochemical properties of nanoparticles, we establish a basis for designing intravitreal nanoparticles to optimize drug delivery and drug retention in the retina. Furthermore, we review recent nanoparticle-based intravitreal therapeutic strategies to highlight their potential to improve AMD treatment efficiency. Lastly, we address the challenges and opportunities in this field, providing insights into the future of nanoparticle-based drug delivery to improve therapeutic outcomes for AMD patients.

1.2 Diabetic macular edemas:

Diabetic macular edema (DME) represents a prevalent and disabling eye condition. Despite that DME represents a sight-threatening condition, it is also among the most accessible to treatments. Many different treatment options including photocoagulation, intravitreal medical treatment (either vascular endothelial growth factor inhibitors or corticosteroid therapies), and surgical removal are currently available. Although laser has been considered the gold standard for many years, over the past several years vascular endothelial growth factor inhibitors (anti-VEGFs) have become first-line therapy. However, many patients do not adequately respond to them. With the development of sustained-release corticosteroid devices, steroids have gained a presence in the management of DME. We review and update the role of anti-VEGF and intravitreal sustained-release corticosteroid management of DME. According to the currently available scientific evidence, the choice of one anti-VEGF over another critically depends on the baseline best-corrected visual acuity (BCVA). While aflibercept may be the drug of choice in low baseline BCVA, the three anti-VEGFs (bevacizumab, ranibizumab, and aflibercept) provided similar functional outcomes when the baseline BCVA was higher. DEX implants are a valuable option for treating DME, although they are usually seen as a second choice, particularly in those eyes that have an insufficient response to anti-VEGF. e new evidence suggested that, in eyes that did not adequately respond to anti-VEGF, switching to a DEX implant at the time to 3 monthly anti-VEGF injections provided better functional outcomes.

1.3 Macular edemas secondary to retinal vein occlusion (RVO):

Retinal vein occlusion (RVO) is the second most common cause of vision loss due to retinal vascular disease, after diabetic retinopathy. Macular edema (ME) is a frequent and sight-threatening complication of both central (CRVO) and branch (BRVO) retinal vein occlusion in the past, treatment options for ME secondary to RVO were limited. e CRVO study group demonstrated that grid laser photocoagulation is not effective in cases of visual impairment due to CRVO-related ME, while the BRVO study group reported its efficacy in treating ME secondary to BRVO. Since the publication of those two reports, the standard of care for BRVO-related ME became grid laser photocoagulation and for CRVO-related ME was observation. However, evidence from subsequent randomized controlled trials has demonstrated significant visual and anatomic improvements among patients with either CRVO or BRVO-related ME who were treated with intravitreal injections of vascular endothelial growth factor (VEGF) inhibitors or with corticosteroids.

1.4 Uveitic Macular Edema:

Macular edema is a major cause of visual impairment in ocular inflammatory disease. Topical corticosteroids are used to treat anterior segment inflammation and may effectively treat ME secondary to chronic iritis or intermediate uveitis. Intravitreal or periocular steroid injections, systemic steroids, or immunosuppressive agents are the treatment of choice in cases where topical steroids are ineffective. Intravitreal injection of 4 mg triamcinolone was proven to be effective in clinical and angiographic resolution of the ME. Uveitis is a common cause of blindness, especially at working age and in low- or middle-income countries. There are many causes of ME, but secondary edema caused by uveitis has perhaps one of the most complex and varied path mechanisms. ME occurs in 8.3% of non-infectious uveitis patients. It can persist without any sign of concurrent inflammation, but active inflammation can make ME difficult to treat.

1.5 Steroids and Macular Edema:

Macular edema, a condition usually associated with an underlying disease process, is a common cause of severe visual loss. There have been a variety of approaches to the treatment of macular edema; within the past few years, however, intravitreal corticosteroid treatments have emerged as an increasingly used treatment option for patients with macular edema. Intravitreal delivery allows the steroids to bypass the blood-retinal barrier, leading to a more concentrated dose of steroids for a prolonged period. Corticosteroids have likely been successful in the treatment of various forms of macular edema, due to their known anti-angiogenic, anti-edematous, anti-inflammatory, anti-apoptotic, and antiproliferative effects. Intravitreal triamcinolone acetonide has been repeatedly successful in reducing macular edema and improving visual acuity, although the duration of action is typically short-term. Due to the recurrent and chronic nature of macular edema, biodegradable implants may be the future of intravitreal steroids. Intravitreal corticosteroids are not without risks. Steroid-related side effects include cataract formation and elevated intraocular pressure. Injection-related side effects include retinal detachment, vitreous hemorrhage, bacterial endophthalmitis, and sterile endophthalmitis.

Macular edema is most commonly secondary to venous occlusive disease, diabetic retinopathy, and posterior segment inflammatory diseases. Corticosteroids can be used to treat ME because of their antiangiogenic, antiedematous, anti-inflammatory, and antiproliferative effects.8Y10 They inhibit phospholipase A2 induction through lipocortin production.11 Corticosteroids have also been shown to down-regulate many inflammatory mediators including interleukins, prostaglandins, and tumor necrosis factor. High doses of systemic corticosteroids can be used to treat ME, but they may cause a spectrum of systemic adverse effects including osteoporosis, Cushing syndrome, alteration of mental state, adrenal suppression, and exacerbation of diabetes and hypertension.12 In the wake of these not-uncommon adverse ties associated with systemic steroids, intravitreal delivery of corticosteroids may allow many posterior segment diseases to be treated locally, with the theoretical benefit of improved steroid vitreal bioavailability

(2) EQUIPMENT:

Anti-VEGF drug
Syringe – usually 1 ml as only a very small volume (0.05–0.1 ml) is injected
Large bore needle – for drawing up the drug
30g needle – for giving an injection
5% (aqueous) povidone-iodine solution for disinfection of skin and conjunctiva
Local anesthetic drops
Topical antibiotic drops
Sterile cotton buds
Sterile gloves
Drapes
Eyelid speculum
A caliper or other measuring device

(3) PROCEDURE:

- Most patients will be understandably nervous about the prospect of having a needle stuck into their eye. You must provide sensible reassurance, and explain every step of the procedure so that your patient knows exactly what is going to happen next.
- Before you do anything to your patient, check the notes and prescription. You cannot see which eye needs to be treated so make sure that you are planning to inject the correct eye with the right drug. It is advisable to mark the eye to avoid any possible confusion.
- Once the patient is lying down comfortably, scrub your hands and put on sterile gloves. Some people will wear a sterile gown, but this is not essential.
- Instil some local anesthetic drops. I usually put drops in both eyes, as the iodine solution is very irritant and may go into the other eye.
- The drops take a few minutes to work, so draw up the anti-VEGF while you are waiting. Use a sterile technique to draw up 0.1 ml into the 1 ml syringe, using a large bore needle. Empty the air from the syringe and fit the 30G needle on the syringe. Eject the surplus drug until there is 0.05ml left in the syringe.
- Use the 5% aqueous povidone-iodine solution to clean and disinfect the eye to be injected. Wipe the skin around the eye and ensure that the solution goes into the conjunctival sac so that it also disinfects the surface of the eye. Leave the eye for a minute or so for the solution to work.
- Instil some topical antibiotic drops (the patient must complete the course).

- Dry the skin around the eye to remove excess povidone-iodine and place a sterile drape over your patient's face so
- that only the eye to be treated is visible. Arrange the drape so that it does not obstruct your patient's breathing. Insert the speculum to hold the eye open (Figure 1).
- I usually place a swab soaked in local anesthetic over the site of the injection and hold it in place for one minute (Figure 2)
- Using the measuring caliper or some other measuring device (Figure 3), measure a safe distance behind the limbus in the inferotemporal quadrant. In patients who have had cataract surgery, this is 3.5 mm. In patients who are phakic and still have their lenses, it is 4 mm.
- Warn the patient that you are about to inject, insert the needle quickly and inject the drug (Figure 4), then remove the needle. Tell your patient it is all over!
- Instil more topical antibiotic drops, and check that the patient's vision is unaffected. Sometimes injection of even a small volume of fluid will cause a sharp rise in intraocular pressure. If this happens, the patients will notice a loss of vision. The best treatment is to do an immediate paracentesis to release aqueous from the anterior chamber. If this is not possible, however, ocular massage will usually lower the IOP. In patients who are at high risk from an elevation of IOP (e.g. people with severe glaucoma), it is sensible to do an ocular massage before giving the injection.
- You should prescribe topical antibiotic drops for 4 days after the injection. You must also make follow-up arrangements, either for another injection or to be reviewed in the clinic.

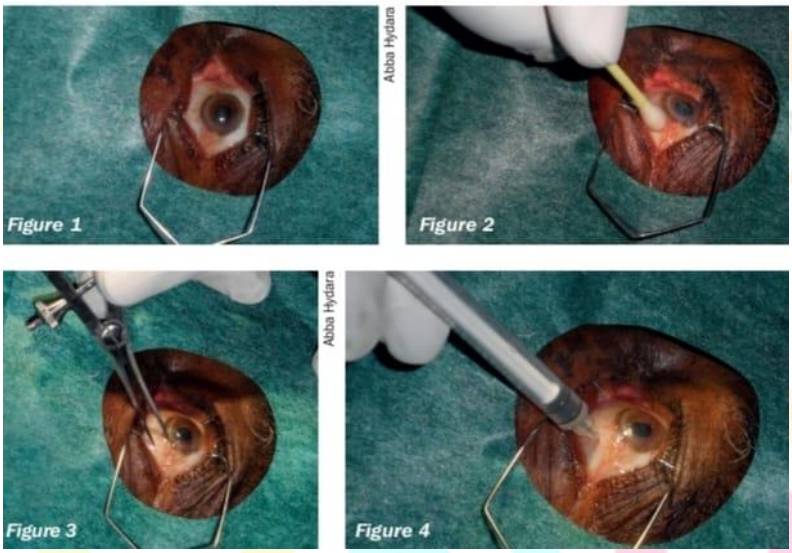

Fig no 1: Intravitreal injection technique

(4) Advancement in tecnniques:

4.1 Imaging Guidance:

Age-related macular degeneration (AMD) is a leading cause of vision loss in the elderly, with dry AMD (d-AMD) leading to geographic atrophy (GA) and significant visual impairment. Multimodal imaging is crucial in d-AMD diagnosis and management, allowing for detailed classification of patient phenotypes and aiding in treatment planning and prognosis determination. Treatment approaches for d-AMD have recently witnessed profound change with the development of specific drugs targeting the complement cascade, with the first.

anticomplement agents recently approved for GA treatment. Additionally, emerging strategies such as gene therapy and laser treatments may offer potential benefits, though further research is needed to establish their efficacy fully. However, the lack of effective treatments restoring damaged retinal cells remains a major challenge. In the future, genetic treatments aimed at preventing the progression of d-AMD may emerge as a powerful approach. Currently, however, their development is still in the early stages.

4.2 Needle Design:

This study proposes a new design for the needle tip for use in IVIs, which can reduce ocular tissue trauma and significantly decrease the capture of the cellular content inside the needle tip. Cytological study of needle tip aspirates demonstrated almost 50% less cellular content discovered from the NDN in comparison to the SHN. The required penetration force of the prototype NDN was higher than that of the SHN, which would need to be solved through an improved manufacturing process. The role of the cellular content, which could be potentially injected into the vitreous, has to be taken into consideration. The clinical significance of the new design of the needle prototype shall be further investigated.

4.3 Injection Techniques:

Our findings are in line with the notions expressed in international guidelines and consensus papers for the administration of intravitreal anti-VEGF injections and provide clear evidence for decreased pain with the use of 30-gauge or thinner needle sizes. In drug development, we recommend exploring the thinnest feasible gauge size to minimize patient discomfort. Patients undergoing intravitreal anti-VEGF therapy with intravitreal injections were included. We did not enforce any criteria on the decision for intravitreal anti-VEGF therapy. No restrictions were made on patient characteristics (e.g., age, sex, race) or any eye characteristics (e.g., phakic/pseudophakic, underlying disease, visual acuity). We did not enforce any restrictions on the anti-VEGF drug employed for such a study; however, intravitreal anti-VEGF therapy considered outside the definition of routine intravitreal anti-VEGF therapy was not eligible for this study (e.g., port delivery devices, experimental delivery systems, implant-based systems). Intravitreal therapy without any anti-VEGF or a combination of anti-VEGF with any other drug category (e.g., antibiotics or corticosteroids) was not considered eligible for this study. We did not enforce any restrictions on the protocol for topical anesthesia but noted such details for the qualitative review.

Our outcome of interest was the pain experience. We did not apply restrictions on the measure used to report on pain experience. We required that pain was reported by the patient (i.e., not a bystander or the injection provider) and that pain was measured immediately after the injection procedure

4.5 Sterility and Safety:

The first step for improving the safety of IVT injection is selecting the appropriate environment for the injection. Some clinicians prefer to use a clinic room for convenience, whereas others advocate the use of a sterile operating room. Tabandeh et al showed the rate of endophthalmitis after IV injections performed in a sterile operating room setting to be as low as 0.0075% per injection. A retrospective comparative study in 2 different settings found that the rates of endophthalmitis were low and appeared similar, 0.035% in the office-based examination room and 0.065% per injection in the operating room. With limited data available in the literature and inconsistent results, further randomized controlled trials are warranted

(5) Advancements in Therapeutics:

5.1 Anti-Vascular Endothelial Growth Factor (Anti-VEGF) Agents:

Intravitreal injections of anti-vascular endothelial growth factor (anti-VEGF) are the most commonly performed intraocular treatment worldwide. The number of indications for their use has increased throughout the years, as anti-VEGF therapy has become the main stay of treatment for several common retinal diseases including neovascular age-related macular degeneration (AMD). Rarely, this treatment may lead to adverse events such as intraocular hemorrhage, retinal detachment, endophthalmitis and intraocular inflammation. Of these complications intraocular inflammation (IOI) is of particular interest as increased rates have been noted with more recent antiangiogenic drugs. This inflammation may range from a mild transient reaction to potentially vision-threatening outcome after intravitreal injection of anti-VEGF therapy. Since it may be easily mistaken for infectious endophthalmitis, a clear understanding of this pathology is essential. Infectious endophthalmitis is usually associated with pain, hypopyon, severe anterior chamber reaction, hyperemia, and significant vision loss, while symptoms associated with sterile endophthalmitis are less severe. In order to decrease the rates of inflammation, it is critical to consider all factors that may play a role both in clinical practice and pharmaceutical development.

5.2 Corticosteroids:

Diabetic macular edema (DME) remains an important worldwide cause of visual loss. Corticosteroids have a role in the treatment of some patients with advanced or recurrent DME. The best-studied steroids for this indication are triamcinolone acetonide, dexamethasone, and fluocinolone acetonide. All steroids are associated with risks of cataracts and intraocular pressure elevation. In addition, intravitreal injection of any medication is associated with risks of infectious endophthalmitis, which has led to the investigation of various extended-release steroid implants. At this time, no steroid is approved by the United States Food and Drug Administration (FDA) for the treatment of DME.

5.3 Gene Therapy:

Age-related macular degeneration is a complex, multifactorial disease with aging, environmental/lifestyle, and genetic/epigenetic factors playing a role in its pathogenesis The complexity of this disease is also underlined in that each of these elements has several variants that may interplay both within each group of factors and with factors from a different group. For instance, AMD is not a monogenic disease. As shown in genome-wide association studies, several genetic loci may be involved in its pathogenesis, containing genes of the following three main pathways: the complement pathway, lipid metabolism, and extracellular matrix remodeling. Variants of these genes may interact and their effect can be modulated by environmental/lifestyle AMD risk factors, including an unhealthy diet.

(6) REFERENCE:

1. Reibaldi, M., Fallico, M., Avitabile, T., Marolo, P., Parisi, G., Cennamo, G., ... & Virgili, G. (2022). Frequency of intravitreal anti-VEGF injections and risk of death: a systematic review with meta-analysis. *Ophthalmology Retina*, *6*(5), 369-376.

2. Chan, V. C., Liu, D. T., & Lam, D. S. (2012). An Update on Intravitreal Injections for Macular Diseases: Friend or Foe? *Asia-Pacific Journal of Ophthalmology*, *1*(1), 43-50.

3. Fagan, X. J., & Al-Qureshi, S. (2013). Intravitreal injections: a review of the evidence for best practice. *Clinical & experimental ophthalmology*, *41*(5), 500-507.

4. Nov, E., & Moisseiev, E. (2020). The top 100 most-cited papers on intravitreal injections: a bibliographic perspective. *Clinical Ophthalmology*, 2757-2772.

5. Lam, L. A., Mehta, S., Lad, E. M., Emerson, G. G., Jumper, J. M., Awh, C. C., & Task Force on Intravitreal Injection Supplemental Services. (2021). Intravitreal injection therapy: current techniques and supplemental services. *Journal of VitreoRetinal Diseases*, *5*(5), 438-447.

6. Zhang, Y., Watson, S., Ramaswamy, Y., & Singh, G. (2024). Intravitreal therapeutic nanoparticles for age-related macular degeneration: Design principles, progress and opportunities. *Advances in Colloid and Interface Science*, 103200.

7. Furino, C., Boscia, F., Reibaldi, M., & Alessio, G. (2021). Intravitreal therapy for diabetic macular edema: an update. *Journal of Ophthalmology*, *2021*(1), 6654168.

8. Teper, S. J. (2021). Update on the management of uveitic macular edema. *Journal of Clinical Medicine*, *10*(18), 4133.

9. Yorston, D. (2014). Anti-VEGF drugs in the prevention of blindness. *Community Eye Health*, *27*(87), 47.

10. Servillo, A., Sacconi, R., Oldoni, G., Barlocci, E., Tombolini, B., Battista, M., ... & Querques, G. (2024). Advancements in Imaging and Therapeutic Options for Dry Age-Related Macular Degeneration and Geographic Atrophy. *Ophthalmology and Therapy*, 1-16.

11. Lytvynchuk, L. M., Petrovski, G., Dam, A., Hiemstra, J., Wimmer, T., Savytska, I., ... & Stieger, K. (2021). Novel Needle for Intravitreal Drug Delivery: Comparative Study of Needle Tip Aspirates, Injection Stream and Penetration Forces. *Clinical Ophthalmology*, 723-734.

12. Butler, E. T., Bjerager, J., Eriksen, N. S., Hajari, J. N., Schneider, M., Faber, C., & Subhi, Y. (2024). Effect of Needle Gauge Size on Pain During Intravitreal Anti-VEGF Injection: A Systematic Review and Network Meta-Analysis. *Ophthalmology and Therapy*, *13*(3), 801-817.

13. Blasiak, J., Pawlowska, E., Ciupińska, J., Derwich, M., Szczepanska, J., & Kaarniranta, K. (2024). A New Generation of Gene Therapies as the Future of Wet AMD Treatment. International Journal of Molecular Sciences, 25(4), 2386.

International Research Journal
IJNRD
Research Through Innovation