



HOMOEOPATHIC MIASMATIC MANAGEMENT OF ATOPIC MARCH WITH PSORINUM : A CASE REPORT

Sonny Mon.R¹, Sherohlean.T²

¹Associate Professor, Department of Organon of Medicine, Sarada Krishna Homoeopathic Medical College, (Affiliated to The Tamil Nadu Dr. M.G.R Medical University, Chennai), Kulasekharam, Kanniyakumari District, Tamil Nadu, India

²PG Scholar, Department of Organon of Medicine, Sarada Krishna Homoeopathic Medical College, (Affiliated to The Tamil Nadu Dr.M.G.R Medical University, Chennai), Kulasekharam, Kanniyakumari District, Tamil Nadu, India
Corresponding Author Email: sonnymon79@gmail.com

Abstract : A chronic case of atopic march with strong psoric miasm features presented with persistent skin itching, oozing, and discoloration, with symptoms exacerbated at night, by tight clothing, perspiration, and undressing. The patient had a concurrent history of bronchial asthma, alternating with skin complaints. The patient had been using an inhaler for asthma attacks and ointments for skin issues. The case was successfully managed with the homeopathic remedy Psorinum at a potency of 200. Efficacy was assessed using Numeric rating scale and photographic evidence, demonstrating significant improvement in symptoms.

IndexTerms - Eczema, bronchial asthma, psorinum.

INTRODUCTION

Eczema and bronchial asthma are both chronic inflammatory conditions that often coexist. This connection is part of what's known as the "**atopic march**", a progression of allergic diseases that typically starts with eczema in early childhood, followed by food allergies, allergic rhinitis, and eventually asthma. There is a strong genetic component to both eczema and asthma. Studies have shown that having a family history of asthma or other allergic diseases increases the risk of developing both conditions. This suggests that genetic susceptibility plays a significant role in the development of these diseases. Both conditions are driven by an overactive immune response. These shared immunological mechanisms contribute to the co-occurrence of eczema and asthma.^{1,2}

CASE DESCRIPTION

A female of 42 years complained of small skin eruptions with discoloration, in all fold of skin, elbow bends, in-between thighs, armpits, hips, abdomen (Fig 1) with intense itching aggravated at night, tight clothing, perspiration and after undressing. Skin-cracks at Retroauricular sulcus, with itching and watery discharge, aggravated at night. All complaints aggravated since few weeks and has been existing for several years. Bronchial asthma since past 7 years aggravated during winter. Skin and respiratory complaints alternate each other. She has been taking inhaler during asthma attacks and ointment for her skin complaints. During these external applications she feels better, but they recur. The patient has a strong family history of both bronchial asthma and eczema.

EXAMINATION OF AFFECTED SYSTEM

Skin- dry, dirty discolored in retroauricular region with cracks, mammary region, hips, in between thighs, armpits, elbow bends, and abdomen. No swelling or abnormal growths found. Small discoloured eruptions present. Scratch marks present.

NUMERIC RATING SCALE

1 2 3 4 5 6 7 8 9 10

Respiratory - no added sounds, normal vesicular breathing, no polyps or hypertrophied turbinates, normal contour of chest, no swelling, No visible pulsations or scar marks.

Table 1:Repertorial chart

Remedy Name	Psor	Graph	Merc	Rhus-t	Mez
Totally / Symptom Covered	12 / 5	8 / 4	8 / 4	8 / 4	7 / 5
[Kent] [Ear]Eruptions:Behind ears:Eczema: (7)	3	3			
[Kent] [Chest]Eruptions:Axilla:Eczema: (7)	3		1		
[Kent] [Extremities]Eruption:Elbow:Bend of:Eczema: (4)	3	2			2
[Kent] [Extremities]Eruption:Lower limbs:Eczema: (11)	2		1	2	
[Kent] [Skin]Eruptions:Alternating with :Respiratory symptoms:Asthma: (4)				1	1
[Kent] [Skin]Eruptions:Itching:Night: (18)		1	3	2	2
[Kent] [Sleep]Sleeplessness: (226)	1	2	3	3	1
[Kent] [Skin]Itching:Undressing agg: (25)					1

MEDICINE PRESCRIBED

24/07/2024

Rx

PSORINUM 200/ 1D (HS) on the first visit.

After every dose of psorinum per week, the following week was prescribed with sac lac.(table 2)

BASIS OF SELECTION


PSORINUM

- ❖ The therapeutic field of this remedy is found in so-called psoric manifestations.
- ❖ Ailment from suppressed itch.
- ❖ Psorinum is a cold medicine. Extreme sensitiveness to cold.
- ❖ Scrofulous patients. Skin symptoms very prominent. Folds of skin.
- ❖ Asthma, with dyspnea;Cough returns every winter, from suppressed eruption.
- ❖ Skin Dirty. Intolerable itching.
- ❖ Eczema behind ears, humid scurfs. ^{3,4}

Table 2: Follow up

Date	Symptom(s)changes	Prescription
31/07/24	Eczema persits, Breathing difficulty persists <i>Generals</i> All good BP - 120/80mmHg	Rx 1. SAC LAC /1D (HS) X 2 weeks
14/08/24	Eczema persists, Breathing difficulty persists <i>Generals</i> Sleep - reduced O/E Chest - mild wheeze BP - 110/80mmHg	Rx 1. PSORINUM 200/1D(HS) X 1 week
28/08/24	Eczema with, Itching present, better than before and almost relieved Breathing difficulty 75% better <i>Generals</i> Thirst - reduced BP - 110/90mmHg	Rx 1. PSORINUM 200 / 1 D(HS) X 1 week
18/09/24	Eczema better, Breathing difficulty increased since 2 days A/F - Climate change <night <i>Generals</i> All good BP - 130/70mmHg	Rx 1.PSORINUM 200 / 1 D(HS) X 1 week

NUMERIC RATING SCALE



PHOTOGRAPHIC EVIDENCE

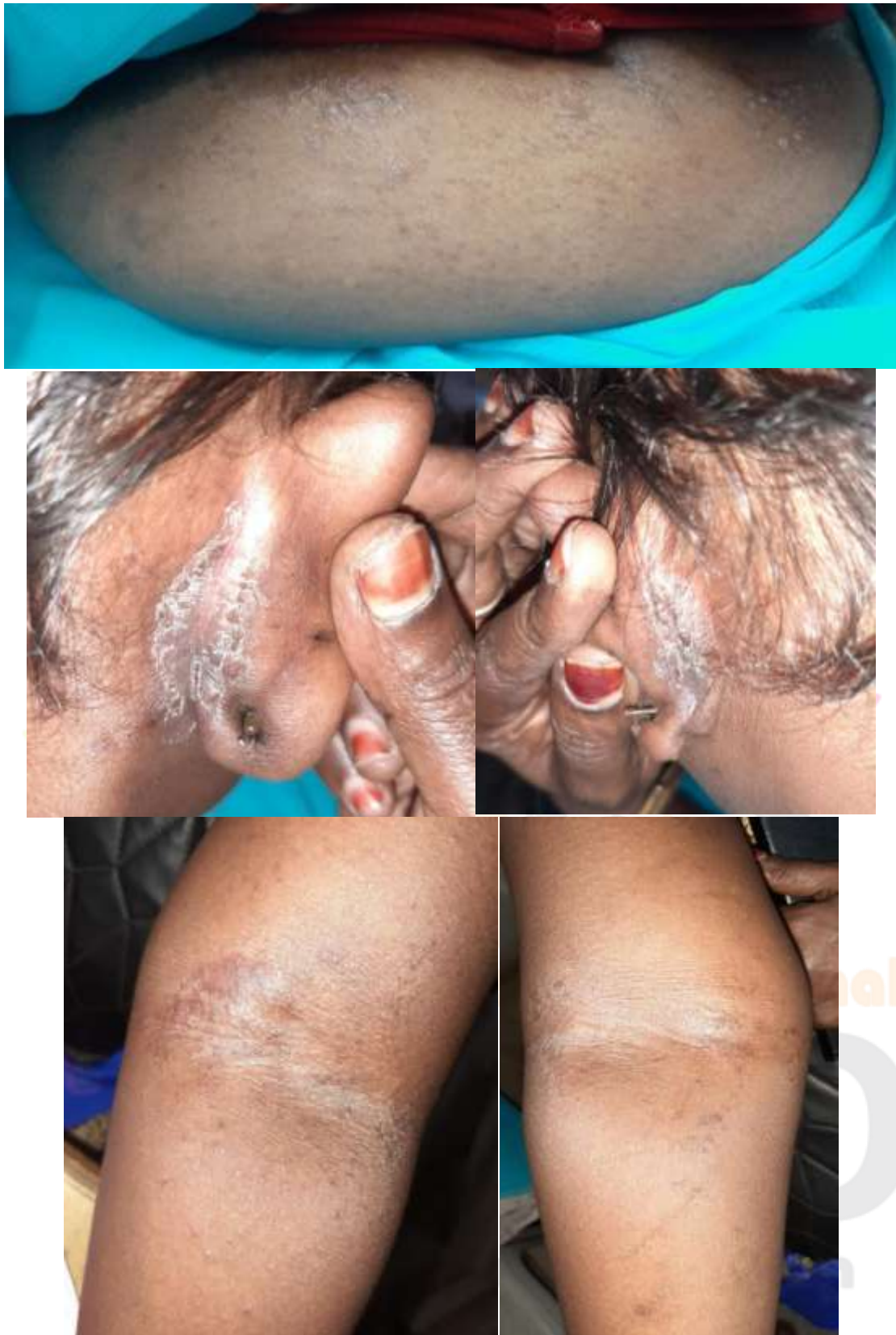

Figure 1: Before treatment (24/07/2024)

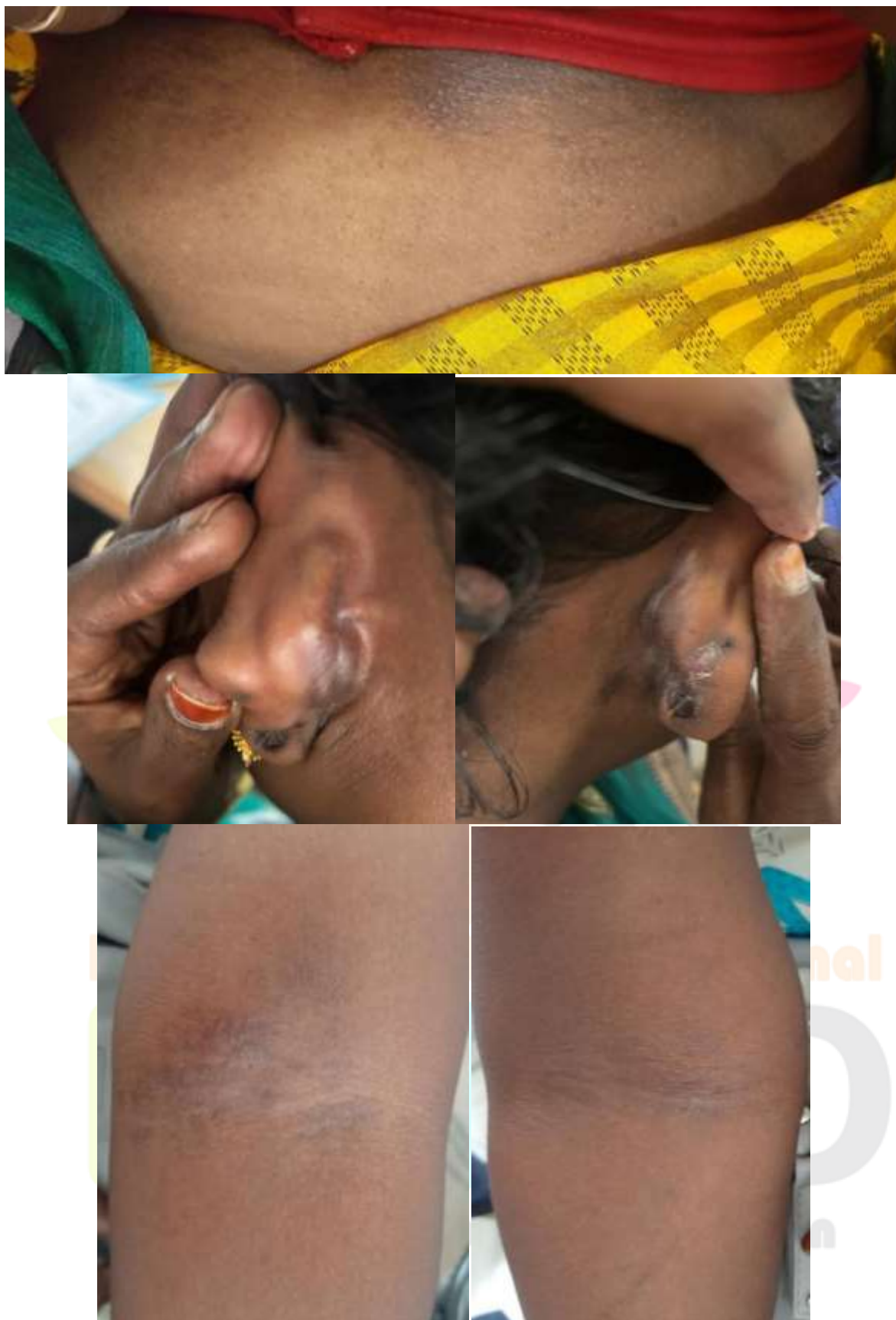

Figure 2: After treatment (18/09/2024)

DISCUSSION

The predominant miasm found in this case is psora, and the prescription is psorinum, having a strong family history of eczema and asthma. A paper “The homeopathic treatment of asthma and allergies” says that psora is found more predominantly in allergic diseases, the important characteristic of psora is that it has strong family history of one or more of the triad of asthma, eczema and hayfever and the antipsorics notably used are psorinum and sulphur.⁵

The use of ointments for years over the eruptions caused suppression of the internal nature of disease leading to development of asthma. The superficial symptoms are driven deep into the vital organs by means of suppression.

In aphorism 204 Hahnemann states that, “most of the chronic diseases result from the development of these three chronic miasms, internal syphilis, internal sycosis, but chiefly and in infinitely greater proportion, internal psora, each of which was already

in possession of the whole organism, and had penetrated it in all directions before the appearance of the primary, vicarious local symptom of each of them that prevented their outburst; and these chronic miasmatic diseases, if deprived of their local symptom, are inevitably destined by mighty Nature sooner or later to become developed and to burst forth, and thereby propagate all the nameless misery, physicians striven in a rational manner to cure radically and to extinguish in the organism these three miasms by the internal homoeopathic medicines suited for each of them, without employing topical remedies for their external symptoms.”⁶ After our homoeopathic prescription the patient was asked to stop using external applications for her skin troubles and was advised to maintain personal hygiene.

CONCLUSION

This case has exhibited the transformation of disease from one part to another which resulted from suppression and it shows that through proper history taking and collection of family history a proper miasmatic approach can be made and the disease can be managed without the help of external applications. Psorinum has proved its efficacy in the potency 200 when given once in two weeks. The numeric assessment scale shows improvement as well as the photographic evidence exhibit the efficacy of homoeopathy without the use of any external application.

ACKNOWLEDGMENT

I sincerely express my heart felt gratitude to my professors and head, Department of Organon of medicine, and the institution SKHMC for the invaluable guidance, support and encouragement throughout the preparation of this case report.

REFERENCES

- [1] Dharmage SC, Lowe AJ, Matheson MC, Burgess JA, Allen KJ, Abramson MJ. Atopic dermatitis and the atopic march revisited. *Allergy*. 2014 Jan;69(1):17-27.
- [2] Hill DA, Spergel JM. The atopic march: critical evidence and clinical relevance. *Annals of Allergy, Asthma & Immunology*. 2018 Feb 1;120(2):131-7.
- [3] Boericke W. *New manual of homoeopathic materia medica and repertory*. B. Jain Publishers; 2002.
- [4] Allen HC. *Allen’s Keynotes: Rearranged & Classified*. B. Jain Publishers; 2002.
- [5] Wallace KR. The homoeopathic treatment of asthma and allergies. *British Homeopathic Journal*. 1986 Oct;75(04):218-26.
- [6] Hahnemann s. *Organon of medicine*. B. Jain publishers; 2005.

