INTERNATIONAL JOURNAL OF NOVEL RESEARCH AND DEVELOPMENT (IJNRD)
© 2026 IJNRD | Volume 11, Issue 10, October 2026 | ISSN: 2456-4184 | IJNRD.ORG

A SINGLE CASE STUDY ON SURGICAL MANAGEMENT OF PHIMOSIS

Dr. Shubha M M[1], Dr. Siddayya Aradhyamath[2], Dr. Sushmitha M R[3], Dr. Priyadarshini Karanji[4]

Final Year PG Scholar, Department of PG & Ph.D Studies in Shalya Tantra, JSS Ayurveda Medical College, Mysuru, Karnataka, India

Professor and Head of Department, Department of PG & Ph.D Studies in Shalya Tantra, JSS Ayurveda Medical College, Mysuru, Karnataka, India

Final Year PG Scholar, Department of PG & Ph.D Studies in Shalya Tantra, JSS Ayurveda Medical College, Mysuru, Karnataka, India

Final Year PG Scholar, Department of PG & Ph.D Studies in Shalya Tantra, JSS Ayurveda Medical College, Mysuru, Karnataka, India

ABSTRACT:

Phimosis is described as condition in which prepuce or foreskin of glans penis is not retracted backwards resulting in poor narrowed stream of urine during micturition causing ballooning of prepuce along with recurrent attacks of balanoposthitis and Urinary Tract Infections (UTIs). The treatment of phimosis varies depending on the age of the patient and the severity of the disease; a great number of conservative or surgical treatments are currently available. There are several treatment modalities are available according to severity of adhesions such as local application of steroid cream or oil, manual retraction, dilatation and Circumcision. Concerning the surgical approach, the gold-standard treatment is represented by circumcision in which tissue synthesis after prepuce removal can be also obtained with barbed sutures, fibrin glues or staples. In Ayurveda Samhita Niruddha Prakash (phimosis) vyadhi (disease) is described to be formed because of vitiated Vata Dosha where constricted Shishnacharma (prepuce) covers Mani (glans penis). This creates obstructed, slow urine flow and the prepuce could not be retracted. Treatment described in Ayurveda is dilatation of preputial meatus by Niruddhaprakash Nadiyantra and Vatadosh Shamak medicated taila (oil) Parisheka (fomentation). A male patient aged 35years visited our OPD with complaints of inability to retract the preputial skin with thin stream of urine and painful intercourse (Dyspareunia) since 3months. Patient was diagnosed with Phimosis and underwent surgical intervention for its correction.

KEY WORDS: Phimosis, Circumcision, Nirudhaprakasha

INTRODUCTION:

Phimosis is defined as the inability of the prepuce (foreskin) to be retracted behind the glans penis in males. Word Phimosis originated from Greek- literal meaning is “Muzzling.” (To Cover or Envelop). The history of non-retractile foreskin and preputial adhesions was extensively documented in the mid- 20th century, first by Gairdner in 1949 and then Oster in 1968. The studies show that in most of the boys the foreskin will be retractile, once the boys mature into their teenage years. The study demonstrated that Physiological Phimosis is present in 8% of 6 to 7year-old, 6% of 10 to 11year-old and 1% of 16 to 17year-old boys. This condition can be congenital (primary, without signs of scarring) or acquired (secondary and pathological); the latter is a consequence of local inflammation (recurrent balanitis or balanoposthitis) or infections due to poor hygiene[1]. Some diseases like diabetes mellitus and lichen sclerosus (LS) could also cause phimosis[2,3]. It is mostly common in children in the first decade of life with a second peak of incidence occurring after the sixth decade of life[4]. Majority of new born boys do have non-retractile foreskin called as Physiological Phimosis. Physiological phimosis usually does not require any kind of treatment as it resolve spontaneously within first couple of years mostly taking 3 to 6 years after which measures are considered to correct it surgically. Pathological phimosis is condition in which prepuce get adhered to glans secondary to adhesions or scarring made because of infection, inflammation

or trauma. Pathological phimosis and physiological phimosis with recurrent attack of balanoposthitis and UTIs do require treatment.

Symptoms include straining during micturition, poor stream of urine, burning micturition or recurrent attacks of Balanoposthitis.[5] Preputial skin covers the whole glans and obstruct the flow of urine resulting in poor stream of urine which may or may not be associated with pain.[6] Inability to retract prepuce manually and ballooning of preputial skin observed during micturition is confirmatory of diagnosis of Phimosis.[7]Phimosis should be differentiated from paraphimosis in which retracted foreskin causes obstruction to the venous outflow leading to swollen, oedematous and congested glans penis.[8] Meatal stenosis and hypospadias must be ruled out as these conditions may or may not be associated with phimosis and can be missed as glans is covered by adhered preputial skin.

About the surgical approach, circumcision remains the gold standard. Circumcision is a surgical procedure that involves partial or complete removal of the foreskin of the penis. Word circumcision comes from Latin: circum = around, and caedere = to cut. Circumcised men are estimated to constitute 37-39% of the world's male population as of 2021. It is practiced in about 15% of males. The first evidence of circumcision comes from early Egyptian wall paintings that are more than 5000 years old. It is integral part of the religious law and established practice in Jews and Islam. Bleeding, pain, urinary retention, recurrent phimosis, redundant skin, wound infection, necrosis, fistulas, iatrogenic hypospadias and epispadias, meatitis, meatal stenosis, concealed penis[9], non-satisfying cosmetic appearance, and impotence are the described complications, most of which may significantly impact on healthcare costs and on the patient's quality of life[10.]

According to Acharya Sushrutha, Niruddha Prakasha vyadhi is caused due to vitiated Vata dosha in Shishnacharma (prepuce) covering Mani (glans penis), this creates obstruction, thin urine flow and the prepuce cannot be retracted.[11] Parivartika and Nirudhaprakash are two diseases of Shishna, explained under Kshudraroga by Acharya Sushruta, can be co-related to Paraphimosis and Phimosis respectively.[12] Conservative and surgical management of nirudhaprakasha is explained in Sushrutha samhitha. Acharya Sushrutha describes Louha nadi with openings at both the ends is applied with Ghrita to lubricate and then penetrated it slowly into preputial opening. Then Mani parisheka is done with Vasa, Majja of Shishumara and Varaha as well as Chakrataila of vataghna dravyas.[13] (Nibandhasangraha commentary of Susruta samhita describes Chakratail as Yantrapidita taila meaning oil extracted by cold pressed method). After consecutive three days larger Nadi should be used in sequence. Snigdhannapana should be given during this treatment. Acharya Sushrutha also mentions about Circumcision by preserving Sevani (frenulum) and it is treated as Sadyakshata/ Sadyovrana.[14] Similar treatment and surgery are advised in Astangahridaya and Astangasangraha.[15]

CASE DESCRIPTION:

HISTORY

A male patient aged 35years visited our OPD with complaints of inability to retract the preputial skin with thin stream of urine and painful intercourse (Dyspareunia) since 3months.

LOCAL EXAMINATION

On Inspection

• Scar marks - absent

• Discolouration - present

• Swelling/Ballooning - present

• Ulcerations - present

• Discharge – present

On Palpation

• Tenderness - present

• Inability to retract prepuce – present

INVESTIGATIONS:

All hematological investigations, Urine routine, Chest Xray, USG scan of abdomen was done prior to surgery. All reports were within normal limit.

DIFFERENTIAL DIAGNOSIS:

Para-phimosis, Balanitis xerotica obliterans (BXO), Ca of Penis, Carcinoma Condyloma warts, Balanitis, Acute Balanoposthitis

DIAGNOSIS: Phimosis

TREATMENT:

MEDICAL CARE - Personal hygiene, Applications of steroid creams (0.05% betamethasone), Topical Antibiotics and Antifungals.

SURGICAL CARE - Circumcision

PRE - OPERATIVE PROCEDURE:

Informed and written consent was taken. Subject was kept NBM for 6 hours prior to surgery. Part preparation was done. Injection TT 0.5 ml IM stat was given. Injection Lignocaine 2% test dose 0.1ml subcutaneous was given.

OPERATIVE PROCEDURE:

DORSAL SLIT TECHNIQUE /FREE-HAND CIRCUMCISION: It is the classical surgical circumcision performed under Spinal anesthesia. In this procedure, the prepuce is freed from the adhesions of glans. Prepuce is held in the artery forceps and gently stretched, circumferential incision on the penile skin is made at the level of corona Prepuce. Then slit up prepuce dorsally within 1cm from corona. Under surface of prepuce is separated from glans. Leaving about 0.5cm of the inner layer of prepuce distal to corona, circumferential incision is made. Cutting the remaining connective tissue completes the excision. Complete haemostasis was achieved by Bipolar diathermy. A Figure of 8 shaped suture is taken over the Frenulum and Frenular artery is ligated. The entire cut edges of the redundant foreskin are approximated to the penile shaft and sutured with Vicryl 2-0/3-0 by simple interrupted sutures.

POST - OPERATIVE CARE:

After Circumcision NBM for 4-6 hours. Analgesics and Antibiotics was administered. IV fluids were started. Vitals were monitored. Hygiene was maintained. Daily dressing done with Antiseptic ointments.

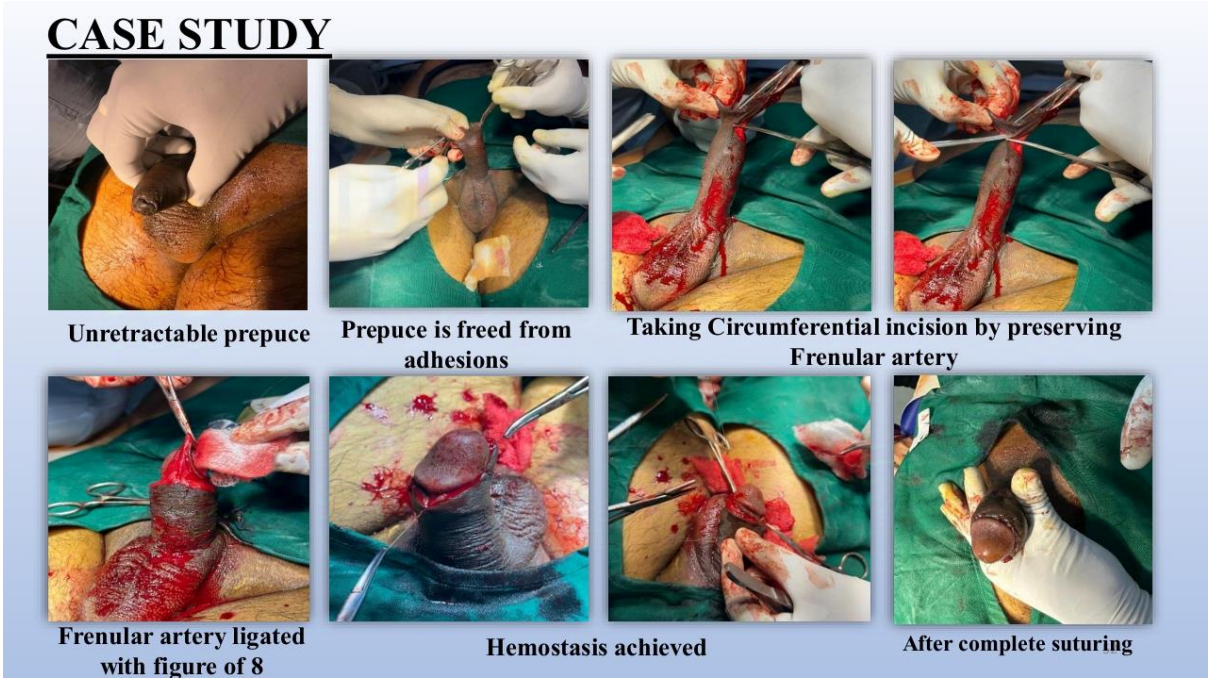

DISCUSSION:

Phimosis can be compared with Niruddha Prakasha in our classics. Understanding of disease stated by various Acharyas, as vata gets aggravated in Mutravaha srotas giving raise to the following symptoms, here both Acharya Sushrutha and Vagbhata mentioned painless thin stream of urine. Whereas, Bhoja explained slow frequent urination, difficulty in micturition and tearing pain in preputial skin, this indicates the clear understanding of infective condition which are apt till date. Procedure of Urethral dilatation and lubrication has been described in classics and contemporary science, hence knowing the limitations of medical management which has no permanent cure, Acharyas has explained surgical procedure (Circumcision) for permanent solution.

Acharya Sushrutha has explained the surgical line of treatment, where he emphasized on preserving the sevani. (during surgery, similarly Contemporary science also states the importance of estimation of the foreskin and frenular artery during circumcision). Though there are many techniques for the management of circumcision. The choice of method in children would be Plastibell and Clamp techniques where as in adult Dorsal Slit Still is the gold standard surgery for Phimosis. Advanced is the ZSR technique. Acharya states the post-operative management of circumcised wound as Sadyovranavath chikitsa. Similarly in contemporary science the foreskin is sutured and bandaged followed by cleaning and dressing until complete healing.

CONCLUSION:

Phimosis is a social stigma, which needs prompt diagnosis and treatment. Management of phimosis is Purely Surgical for Fifth grade of phimosis. Whereas, other four grades can be managed by conservative line of treatment. Circumcision is considered as Ideal surgical technique for the management of phimosis with almost no recurrence. The principles of treatment in Ayurveda remains the same as that of contemporary science. Medical and religious authorities should take proper action to promote awareness on unethical practice of circumcision.

REFERENCES:

1. Palmer, L.S.; Palmer, J.S. Management of abnormalities of the external genitalia in boys. In CampbellWalsh Urology, 11th ed.; Elsevier: Philadelphia, PA, USA, 2016; Volume 4.
2. Gairdner, D. The fate of the foreskin, a study of circumcision. Br. Med. J. 1949, 2, 1433–1437. [CrossRef]

3. Czajkowski, M.; ˙ Zawrocki, A.; Czajkowska, K.; Kł ˛ acz, J.; Sokołowska-Wojdyło, M.; Biernat, W.; Matuszewski, M. Lichen Sclerosus and Phimosis—Discrepancies between Clinical and Pathological Diagnosis and Its Consequences. Urology 2021, 148, 274–279. [CrossRef] [PubMed]
4. Korkes, F.; Silva, J.L.; Pompeo, A.C.L. Circumcisions for medical reasons in the Brazilian public health system: Epidemiology and trends. Einstein 2012, 10, 342–346. [CrossRef] [PubMed]
5. A Parasarthy, IAP Textbook of paediatrics, Fifth edition, Jaypee brothers medical publishers(P)Ltd, 2013, Page 951.
6. Kaviraj Ambikadutt Shastry, Sushruta Samhita of Maharshi Sushruta, Hindi Commentry, Chikitsasthan, Chaukhamba Sanskrit Sansthan,Varanasi, India, Edition 2012, Page 373
7. K. R. Shenoy, Anitha Nileshwar, Manipal Manual of Surgery, Third Edition, Page 796
8. S. Das, A Concise Textbook of Surgery, S Das Publishers, Kolkata, 6th edition, Page 1210,
9. Asimakopoulos, A.D.; Iorio, B.; Vespasiani, G.; Cervelli, V.; Spera, E. Autologous split-thickness skin graft for penile coverage in the treatment of buried (trapped) penis after radical circumcision. BJU Int. 2012, 110, 602–606. [CrossRef] [PubMed]
10. Krill, A.J.; Palmer, L.S.; Palmer, J.S. Complications of circumcision. Sci. World J. 2011, 11, 2458–2468. [CrossRef] [PubMed]
11. Ambikadatta Shastri. Susruta Samhita (purvardha), Varanasi, chaukhamba San skrit pratisthan, 2005 (Reprint edition), p.281-282.
12. Ambikadatta Shastri. Susruta Samhita (purvardha), Varanasi, chaukhamba San skrit pratisthan, 2005(Reprint edition), p.281-282.
13. Vaidya Yadavji Trikamji Acharya, Nara yan Ram Acharya Kavyatirtha. Susruta samhita, Varanasi, Chaukhamba Surbharati Prakashan, 2008 p.480.
14. AmbikadattaShastri. Susruta Samhita (purvardha), Varanasi, chaukhamba San skrit pratisthan, 2005 (Reprint edition), chikitsasthana p.95.
15. Dr Ganesh Krushna Garde. Sartha Vagbhat, Pune, Proficient Publishing House; Reprint 2010 p.520521.

Copyright & License:
© Authors retain the copyright of this article. This work is published under the Creative Commons Attribution 4.0 International License (CC BY 4.0), permitting unrestricted use, distribution, and reproduction in any medium, provided the original work is properly cited.